


**Surgical technique's influence on femoral  
fracture risk and implant fixation.  
Compaction versus conventional bone  
removing techniques.**

**Ph.D. thesis**

**Søren Kold**



**Faculty of Health Sciences  
University of Aarhus  
Denmark  
2002**

From

The Orthopaedic Research Laboratory,  
Department of Orthopaedics,  
Institute of Experimental Clinical Research,  
University Hospital of Aarhus,  
Aarhus, Denmark

&

The Orthopaedic Biomechanics Laboratory,  
University of Minneapolis,  
Minneapolis, MN, USA

**Surgical technique's influence on femoral  
fracture risk and implant fixation.  
Compaction versus conventional bone  
removing techniques.**

**Ph.D. thesis**

**Søren Kold**

**Faculty of Health Sciences  
University of Aarhus  
Denmark  
2002**

*Correspondence:*

*Søren Kold, M.D.  
Orthopaedic Research Laboratory  
Aarhus University Hospital  
Nørrebrogade 44, Building 1A  
DK-8000 Aarhus C  
Denmark  
Phone +45 8949 4134  
Fax +45 8949 4150  
E-mail: s.kold@dadlnet.dk*

---

## ***List of papers***

This thesis is based on the following papers, which will be referred to in the text by their Roman numerals (I-V).

- I. Kold S, Mouzin O, Bourgeault C, Søballe K, Bechtold JE. **Femoral fracture risk in hip arthroplasty: Smooth versus toothed instruments.** *Clin Orthop.* Accepted for publication, 2002.
- II. Kold S, Bourgeault C, Mouzin O, Bechtold JE, Søballe K. **Femoral fracture risk with compaction in cementless hip replacement.** Manuscript, 2002.
- III. Kold S, Rahbek O, Toft M, Overgaard S, Søballe K. **Compaction of existing cancellous bone enhances mechanical fixation of weight-bearing titanium implants. An experimental canine study.** Manuscript, 2002.
- IV. Kold S, Rahbek O, Toft M, Overgaard S, Søballe K. **Compaction of existing cancellous bone enhances mechanical fixation of hydroxyapatite coated implants. An experimental weight-bearing canine study.** Manuscript, 2002.
- V. Kold S, Bechtold JE, Ding M, Chareancholvanich K, Rahbek O, Søballe K. **Compacted cancellous bone has spring-back effect.** Manuscript, 2002.

## **Preface**

The present thesis is based on investigations performed at Orthopaedic Research Laboratory, Department of Orthopaedics, Aarhus University Hospital, Denmark, and at Orthopaedic Biomechanics Laboratory, Minneapolis Medical Research Foundation and Midwest Orthopaedic Research Foundation, Minneapolis, Minnesota, USA. The studies were conducted during my employment as clinical assistant (research fellow) for Professor Kjeld Søballe, M.D., D.M.Sc., in 1999-2002 at the Department of Orthopaedics, Amtssygehuset, Aarhus University Hospital, Denmark. The investigations were performed at the following institutions: Orthopaedic Biomechanics Laboratory, Minneapolis Medical Research Foundation and Midwest Orthopaedic Research Foundation, Minneapolis, Minnesota, USA; Orthopaedic Research Laboratory, Department of Orthopaedics, Aarhus University Hospital, Denmark; Institute of Experimental Clinical Research, University of Aarhus, Denmark; Institute of Pathology, Amtssygehuset, Aarhus University Hospital, Denmark.

The studies were initiated by Professor Kjeld Søballe, M.D., D.M.Sc., to whom I am deeply indebted for providing invaluable support and advice. I thank him for providing excellent working conditions throughout the studies. I also wish to express my deepest gratitude to Associate Professor Joan E. Bechtold, Ph.D., for her constructive criticism and friendship. I thank Joanie for taking good care of my family and me during our stay in Minneapolis. I am very grateful to Associate Professor Søren Overgaard, M.D., D.M.Sc., for his supervision and support.

The conditions for experimental orthopaedic research in Aarhus are outstanding. Professor Otto Sneppen, M.D., D.M.Sc., and Professor Jens Christian Djurhuus, M.D., D.M.Sc., are thanked for their great work in providing excellent working conditions at the Orthopaedic Research Laboratory and Institute of Experimental Clinical Research, respectively.

A special thank is directed to Ole Rahbek, M.D., Ph.D., for introducing me to bone implant research. I thank him for his friendship and for his excellent support and advice. My co-workers Olivier Mouzin, Ph.D., Craig Bourgeault, B.S., Ming Ding, M.D., Marianne Toft, and Keerati Chareancholvanich, M.D., are thanked for their great help in conducting the studies.

Special thanks to Anette Milton and Jane Pauli for their knowledge and skills in preparation of histological sections.

Kristian Hansen, Doug Cooper and Kelly Grimes are thanked for technical assistance. Moreover, thanks to Professor Flemming Melsen, M.D., D.M.Sc., for histological advice; Raymond Gustilo, M.D., for teaching me the compaction procedure; Associate Professor Erik Parner, Department of Biostatistics, University of Aarhus, and Bob Sherman for statistical advice; Anders Bisbjerg Madsen, Ph.D., for mathematical advice. I thank my father, Peder Kold, D.D.S., for introducing me to the field of implantology.

But more than anyone my thanks and love go to my wife Anja Brüggmann, M.D., and our children Eva and Christian for their love, patience and support throughout this work.

## **Acknowledgements**

The studies were supported by grants from the Danish Rheumatism Association, the Institute of Experimental Clinical Research, University of Aarhus, Aarhus University Research Foundation, the Korning Foundation, the Midwest Orthopaedic Research Foundation and Søren Alfred Andersens Legat.

Instruments were kindly provided by Orthopaedic Innovations, Inc., USA, and Biomet-Merck, Denmark. Biomet Inc., USA kindly provided the implants.

## **Preface**

The present thesis is based on investigations performed at Orthopaedic Research Laboratory, Department of Orthopaedics, Aarhus University Hospital, Denmark, and at Orthopaedic Biomechanics Laboratory, Minneapolis Medical Research Foundation and Midwest Orthopaedic Research Foundation, Minneapolis, Minnesota, USA. The studies were conducted during my employment as clinical assistant (research fellow) for Professor Kjeld Søballe, M.D., D.M.Sc., in 1999-2002 at the Department of Orthopaedics, Amtssygehuset, Aarhus University Hospital, Denmark. The investigations were performed at the following institutions: Orthopaedic Biomechanics Laboratory, Minneapolis Medical Research Foundation and Midwest Orthopaedic Research Foundation, Minneapolis, Minnesota, USA; Orthopaedic Research Laboratory, Department of Orthopaedics, Aarhus University Hospital, Denmark; Institute of Experimental Clinical Research, University of Aarhus, Denmark; Institute of Pathology, Amtssygehuset, Aarhus University Hospital, Denmark.

The studies were initiated by Professor Kjeld Søballe, M.D., D.M.Sc., to whom I am deeply indebted for providing invaluable support and advice. I thank him for providing excellent working conditions throughout the studies. I also wish to express my deepest gratitude to Associate Professor Joan E. Bechtold, Ph.D., for her constructive criticism and friendship. I thank Joanie for taking good care of my family and me during our stay in Minneapolis. I am very grateful to Associate Professor Søren Overgaard, M.D., D.M.Sc., for his supervision and support.

The conditions for experimental orthopaedic research in Aarhus are outstanding. Professor Otto Sneppen, M.D., D.M.Sc., and Professor Jens Christian Djurhuus, M.D., D.M.Sc., are thanked for their great work in providing excellent working conditions at the Orthopaedic Research Laboratory and Institute of Experimental Clinical Research, respectively.

A special thank is directed to Ole Rahbek, M.D., Ph.D., for introducing me to bone implant research. I thank him for his friendship and for his excellent support and advice. My co-workers Olivier Mouzin, Ph.D., Craig Bourgeault, B.S., Ming Ding, M.D., Marianne Toft, and Keerati Chareancholvanich, M.D., are thanked for their great help in conducting the studies.

Special thanks to Anette Milton and Jane Pauli for their knowledge and skills in preparation of histological sections.

Kristian Hansen, Doug Cooper and Kelly Grimes are thanked for technical assistance. Moreover, thanks to Professor Flemming Melsen, M.D., D.M.Sc., for histological advice; Raymond Gustilo, M.D., for teaching me the compaction procedure; Associate Professor Erik Parner, Department of Biostatistics, University of Aarhus, and Bob Sherman for statistical advice; Anders Bisbjerg Madsen, Ph.D., for mathematical advice. I thank my father, Peder Kold, D.D.S., for introducing me to the field of implantology.

But more than anyone my thanks and love go to my wife Anja Brüggmann, M.D., and our children Eva and Christian for their love, patience and support throughout this work.

## **Acknowledgements**

The studies were supported by grants from the Danish Rheumatism Association, the Institute of Experimental Clinical Research, University of Aarhus, Aarhus University Research Foundation, the Korning Foundation, the Midwest Orthopaedic Research Foundation and Søren Alfred Andersens Legat.

Instruments were kindly provided by Orthopaedic Innovations, Inc., USA, and Biomet-Merck, Denmark. Biomet Inc., USA kindly provided the implants.

---

## **Contents**

*List of papers, 5*

*Preface, 6*

*Abbreviations, 9*

*Definitions, 10*

*Abstract, 11*

*Introduction, 13*

*Bone implant interface biology, 14*

Bone structure, 14

Bone healing and remodeling around implants, 14

Biological enhancement of bone implant fixation, 15

*Surgical technique, 17*

Bone compaction, 17

*Biomaterials, 20*

Porous-coated implants, 20

Hydroxyapatite, 20

*Aims of experimental studies, 21*

Risk of femoral fracture with compaction, 21

Effect of surgical technique on preoperative to postoperative BMD evaluated by DEXA, 21

Effect of surgical technique on fixation of weight-bearing implants, 21

Spring-back effect of compacted bone, 21

*Methodological considerations, 23*

Experimental subjects, 23

Design of studies, 24

Surgical techniques and instrumentation, 24

*In vitro* model (I, II), 27

Preoperative templating, 27

Experimental *in vitro* fracture model, 27

DEXA scanning, 28

Evaluation of fracture, 29

*In vivo* model (III-V), 29

Experimental animal models, 29

Observation periods, 30

Implant characteristics, 30  
Postoperative animal care, 30  
Preparation of specimens, 30  
Mechanical testing, 31  
Histological and histomorphometric analysis, 32  
Histological sampling, 33  
Tissue implant contact and tissue volume density, 35  
Micro-CT scanning, 35

Reproducibility, 35

Statistics, 36

### ***Results, 37***

Femoral fracture (I, II), 37

BMD evaluated by DEXA (I), 39

Compaction versus drilling in canines (III-V), 39

Excluded animals, 39

Mechanical implant fixation (III, IV), 39

Morphology of peri-implant tissue (III, IV), 40

Tissue implant contact (III, IV), 44

Peri-implant bone density (III, IV), 46

Spring-back (V), 46

### ***Discussion, 47***

Femoral fracture (I, II), 47

Implant fixation (III-V), 49

Clinical implications of compaction, 51

### ***Conclusion, 52***

### ***Suggestions for future research, 53***

### ***References, 54***

### ***Appendix***

Study I

Study II

Study III

Study IV

Study V



---

**Abbreviations**

AGF ®	Autologous growth factor
AP	Antero-posterior
BMD	Bone mineral density
BMP	Bone morphogenetic protein
Ca-P	Calcium phosphate
CT	Computed tomography
CV	Coefficient of variation
DEXA	Dual energy x-ray absorptiometry
FGF	Fibroblast growth factor
HA	Hydroxyapatite
HA implant	Porous-surfaced implant with HA coating
IL-1	Interleukin 1
IL-6	Interleukin 6
IUR	Isotropic uniform random
MMA	Methylmetacrylate
OP-1	Osteogenic protein 1 (BMP-7)
PDGF	Platelet derived growth factor
Psi	Pounds per square inch
QCT	Quantitative computed tomography
RSA	Radiostereometric analysis
SD	Standard deviation
TGF- $\beta$	Transforming growth factor beta
THR	Total hip replacement
Ti	Implant with a plasma-sprayed titanium surface
Ti-6Al-4V	Titanium-6aluminum-4vanadium
TKR	Total knee replacement
TNF- $\alpha$	Tumor necrosis factor alfa

## Definitions

**Aseptic loosening** – Mechanical loosening of a joint replacement implant without infection.

**Biomaterial** – Material intended to interface with biological systems to evaluate, treat, augment or replace any tissue, organ or function of the body<sup>205;206</sup>.

**Bone implant contact** – Bone implant contact was defined as direct contact between bone and implant surface at the light microscopic level.

**Broaching** – Preparation of the implantation site by use of toothed broaches, which are capable of cutting bone.

**Compaction** – A method that compacts or compress the cancellous bone before insertion of an implant.

**Delamination** – Separation of a coating into layers or separation of the entire coating.

**Equivalent circle diameter** – Under the assumption that a circle is a reasonable description of the feature, the measured area of the feature is converted to the linear measure of diameter<sup>158</sup>.

**Exact-fit** – Insertion of an implant into a cavity with similar dimensions as the implant.

**Gruen zones** – Periprosthetic regions of interest around the femoral stem. Gruen zones 7B and 7C are located proximal and medial in the femur<sup>68</sup> (Figure 7).

**Histomorphometry** – Quantitative evaluation of tissue dimensions<sup>140</sup>.

**Implant** – A medical device made from one or more biomaterials that is intentionally placed within the body, either totally or partially buried beneath an epithelial surface<sup>205;206</sup>.

**Lack of HA coating** – A general term used for lack of HA coating on a porous surfaced implant irrespective of the type of mechanism: 1) HA coating had never been present; 2) Loss of HA coating due to biological resorption or mechanical removal (delamination).

**Press-fit** – Insertion of an implant into an under-sized cavity.

**Rasping** – Preparation of the implantation site by use of toothed rasps, which are capable of cutting bone.

**Single pass advancement** – A method to advance the instruments into the femur in single passes instead of alternating between a distal and proximal motion.

**Stereology** – A method by which quantitative information is obtained about three-dimensional structures of objects from two-dimensional sections<sup>70</sup>.

**Stress-shielding** – Proximal bone loss due to by-passing of stresses in the proximal femur as the weight-load and stresses are distributed through the femoral stem.

**Tamping** – A method used for bone compaction, where increasing sizes of smooth tamps compact the cancellous bone.

## Abstract

Initial implant stability is crucial for long-term survival of cementless implants. A new surgical technique, compaction, has been shown to increase implant fixation *in vitro* and during non-weight-bearing *in vivo* conditions. This Ph.D. thesis addresses the potential clinical complication of femoral fracture with compaction, as well as the *in vivo* effects of compaction during weight-bearing conditions. The thesis is based on two experimental studies on human cadaver femurs, and on three experimental animal studies.

Study I and II compared the compaction technique, using smooth, polished tamps for canal preparation, with the conventional broaching and rasping techniques. In both study I and II, the instruments were advanced into the femur by use of a drop tower delivering a controlled impulse, representative of a typical impact during surgery. Study I investigated the surgical technique's influence on femoral fracture risk using instrumentation with a bulky AP design. In addition, study I investigated whether single pass advancement of smooth tamps would increase preoperative to postoperative BMD evaluated by DEXA compared with single pass advancement of toothed broaches. In study I, significantly more femora had fractured at preoperative templated size with tamping (eight of ten) than with broaching (two of ten). Additionally, tamping caused more severe fractures, and less applied work (less overall force) was needed to induce a fracture with tamping than with broaching. Single pass advancement with smooth tamps failed to increase BMD evaluated by DEXA in Gruen Zones 7B and 7C when compared with single pass advancement of toothed broaches.

Study II investigated the surgical technique's influence on femoral fracture risk using instrumentation with a slim AP design. In study II, no significant differences were found in fracture rates between compaction and rasping. However, fractures only occurred in the compaction group. Thus, two of ten femurs in the compaction group had fractured at preoperative templated size. All fractures were longitudinal

fissures in the greater trochanter. These fractures were less severe than the fractures caused by the bulky AP tamps in study I.

Study III and IV compared the effects of compaction versus drilling on weight-bearing implants inserted in the femoral condyle of canines. The hypothesis was that compaction would increase both implant fixation as well as bone implant contact when compared with drilling. In study III, Ti implants were inserted exact-fit, whereas HA implants were inserted press-fit in study IV. After 0, 2, and 4 weeks, implant fixation was examined by push-out test, and histomorphometry was used to evaluate the bone implant contact, and the bone density in a 200  $\mu\text{m}$  peri-implant zone.

In study III, with Ti implants inserted exact-fit, compaction significantly increased ultimate shear strength and energy absorption at 0 and 4 weeks, but not at 2 weeks, compared with drilling. This indicates that compaction exerts both mechanical and biological effects. Bone implant contact and bone density in a 200  $\mu\text{m}$  peri-implant zone were increased by compaction at 0 and 2 weeks, but not at 4 weeks. The increment in bone implant contact at 2 weeks with compaction was due to increased non-vital bone and lamellar bone in contact with the implant. At 2 weeks, a high resorptive activity with resorptive lacunae into the non-vital bone was present in compacted specimens. At 4 weeks, fibrous membranes surrounded two of seven implants inserted with drilling compared with no fibrous membranes in seven compacted specimens.

In study IV, with HA implants inserted press-fit, compaction significantly increased ultimate shear strength at 0 and 2 weeks, but not at 4 weeks, compared with drilling. Energy absorption was significantly increased with compaction at time 0, and nearly significantly increased at 2 weeks, compared with drilling. Compaction significantly increased bone implant contact at time 0, but not at 2 and 4 weeks, compared with drilling. No significant differences were found between compaction and drilling for peri-implant bone density in any of the observation periods.

Study V compared the postoperative diameters of cavities initially prepared to identical dimensions *in vivo* by either compaction or drilling. The hypothesis was that the diameter of compacted cavities would be reduced due to a spring-back effect of compacted bone compared with the diameter of drilled cavities. The specimens were micro-CT scanned, and the equivalent circle diameters of the cavities were calculated. Compaction resulted in postoperative cavities with a significantly smaller equivalent circle diameter than found with drilling. For drilled specimens, the median value of the equivalent circle diameter equaled that of the originally prepared cavities. For compacted specimens the median value of the equivalent circle diameter was 91% of the diameter of the original compacted cavities, demonstrating a spring-back effect of compacted bone.

### **Conclusion**

The present studies demonstrated that smooth tamps increased the risk of femoral fracture compared with toothed broaches when bulky AP instrumentation was used. The risk of femoral fracture with smooth tamps was reduced by slim AP instrumentation.

*In vivo*, compaction yielded superior implant fixation compared with drilling for both Ti implants inserted exact-fit and for HA implants inserted press-fit. For HA implants the superior effects of compaction were present at 0 and 2, but not at 4 weeks. In contrast, for Ti implants a biphasic response of compaction was observed, as superior implant fixation existed in compacted specimens at 0 and 4 weeks, but not at 2 weeks. This biphasic response indicates that compaction exerts both mechanical and biological effects. A spring-back effect, which was demonstrated of compacted bone *in vivo*, offers a possible explanation for the superior implant fixation found with compaction.

## **Introduction**

### **Clinical background**

In Denmark approximately 5000 primary THR are performed per year. The incidence of primary THR is 93 per 100,000 inhabitants in Denmark, and the incidence is increasing due to a higher number of elderly people in the population<sup>116</sup>. In Sweden it has been estimated that the frequency of primary THR should be 130 per 100,000 inhabitants in order to meet the need<sup>79</sup>. The mean age of the patients at the time of surgery is 68 years, and 59% are women<sup>116</sup>. The main indications for primary THR are primary osteoarthritis (75%) and sequelae after proximal femoral fracture (11%)<sup>116</sup>. In the majority of primary THR in Denmark both the femoral and acetabular components are cemented (56%). The cemented THR still remains the gold standard for elderly people. Survival rates for cemented THR continue to increase as modern cementing techniques (careful cleaning of the bone bed, compression of the cement, and vacuum-mixing of the cement to improve its strength) are implemented<sup>79</sup>. The overall risk for revision surgery, defined as exchange of one or both of the components, or removal of the prosthesis, is only 3% after ten years<sup>79</sup>. Thus for the majority of patients, THR is a clinical success as patients are relieved for pain and maintain an acceptable level of physical activity.

Additionally, the economic benefits of THR for the society offset the direct and indirect costs of the treatment even though THR has a significant economic impact on the health care system<sup>16;45</sup>. However, in patients younger than 55 years with a high physical activity, primary THR carry unsatisfactory high revision rates of approximately 20% after ten years<sup>119;120</sup>. The main reason for revision surgery is aseptic loosening (76%). Revision joint replacement implants have shorter longevity, poorer functional outcome, higher costs<sup>50;59;105</sup>, and longer rehabilitation times than primary joint replacements. Therefore, further scientific effort is mandatory to enhance long-term results of THR in the young patients<sup>120</sup>. Clinical studies of cementless implants using RSA have demonstrated that early implant migration is related to late loosening<sup>94;160</sup>. Furthermore, results from the Norwegian Arthroplasty Register have shown that the best results at the femoral side in THR in patients below 60 years of age are achieved with a cementless implant<sup>75</sup>. Thus, research in surgical techniques to optimize early stability of cementless femoral stems seems relevant.

## **Bone implant interface biology**

### **Bone structure**

Cancellous bone is a viscoelastic structure consisting of bone, organized in a lattice structure, and of marrow made up of cells, fat and vessels<sup>114</sup>. Bone tissue consists of cells and extracellular matrix composed of organic and non-organic material. The non-organic part is mainly calcium and phosphate as hydroxyapatite. The organic part consists of collagen and non-collagenous proteins either synthesized by bone cells or exogenously derived and entrapped in the bone matrix. The main organic component is type I collagen, which provides the bone with tensile strength<sup>163</sup>. Several non-collagenous proteins exist of which bone growth factors are primary activators in the two major bone physiological phenomena, bone healing and bone remodeling<sup>113</sup>. Lamellar bone is mature bone arranged in parallel lamellar constituted by collagen fibers which are apparent when viewed by polarization microscopy<sup>28</sup>. Woven bone is immature bone with random orientation of collagen fibers. Woven bone is weaker than lamellar bone<sup>208</sup>. Biomechanically, bone function is provided by orientation of bone trabeculae and osteons which makes bone anisotropic, i.e. with a preferred orientation, both mechanically and morphologically<sup>21;28;61;201;207</sup>. Bone strength is better predicted from orientation of bone lamellae than from bone density<sup>39</sup>.

### **Bone healing and remodeling around implants**

Bone healing around cementless implants resembles fracture healing. Thus during optimal healing conditions, the implant will be anchored by bone ingrowth. However, during suboptimal healing conditions, formation of fibrous scar tissue between implant and bone might occur.

Fractures heal either by primary or secondary healing. In primary healing, bone heals directly through remodeling of osteons in cortical bone. Secondary fracture healing involves formation of either a hard bony callus or a combination of hard bony and soft cartilaginous callus. Bone healing around implants is thought to be secondary with formation of callus.

Fracture healing occurs in sequential phases.

*Inflammatory phase.* Initially a hematoma consisting of platelets and inflammatory cells is formed. The hematoma releases cytokines and growth factors. In addition bone growth factors are released from the traumatized extracellular bone matrix<sup>24</sup>. Thus numerous cytokines and growth factors, including IL-1, IL-6, TNF- $\alpha$ , FGF, PDGF, TGF- $\beta$ , and BMPs, are released into the fracture site<sup>53;126</sup>. The cytokines and growth factors attract primitive mesenchymal cells together with mature osteoclasts and osteoblasts through chemotactic capacities. Furthermore, the growth factors stimulate proliferation and differentiation of mesenchymal stem cells towards an osteoblastic lineage and stimulate the proliferation of mature osteoclasts and osteoblasts<sup>30;153</sup>. BMPs are expressed during the early phases of fracture healing<sup>90;134</sup>, and as the woven bone is replaced with mature lamellar bone, the expression of BMP decreases<sup>17</sup>.

*Resorptive phase.* Osteoclastic resorption has been observed as one of the most dominating processes during the first week after implantation, and the presence of a critical postoperative period in terms of implant stability has been suggested<sup>47</sup>. Thus, during press-fit conditions, bone implant contact decreased temporarily from the 3<sup>rd</sup> to the 14<sup>th</sup> postoperative day prior to a subsequent increase in bone implant contact from the 14<sup>th</sup> to the 28<sup>th</sup> postoperative day<sup>47</sup>. Furthermore a lag time during the initial 4 postoperative weeks has been found before mechanical implant fixation began to increase, and this lag time corresponded to morphological observations of removal of injured bone tissue in the interface<sup>19</sup>.

*Formative phase.* During optimal implant conditions, hard bony callus without cartilaginous intermediates are formed by intramembranous bone formation<sup>126</sup>. The amount of micromotion is critical to bone ingrowth. Bone ingrowth to porous-coated implants occurs in the presence of 20  $\mu\text{m}$ <sup>85</sup> and 28  $\mu\text{m}$ <sup>148</sup> micromotion. Micromotion of 40  $\mu\text{m}$  results in formation of bone, fibrocartilage and fibrous tissue<sup>85</sup>, and micromotions of 150  $\mu\text{m}$ <sup>85;176</sup> and 500  $\mu\text{m}$ <sup>181</sup> result in fibrous encapsulation of porous-coated implants. However, HA coating has the capacity to replace

the motion-induced fibrous membrane with bone<sup>176</sup>, and ingrowth of bone to HA coated implants has been found after 16 weeks of 150  $\mu\text{m}$  continuous micromotion<sup>176</sup>, and after 32 weeks of 250  $\mu\text{m}$  continuous micromotion<sup>141</sup>.

**Remodeling.** During remodeling, the initially formed immature woven bone is replaced by mature lamellar bone with a functional orientation. In an animal study, newly formed lamellar bone with a different orientation from that in the original lamellar bone has been observed as early as 4 weeks after implantation<sup>47</sup>. The final strength of the bone implant interface depends not only on the amount of ingrown trabeculae, but also on the maturation of the mineralized bone matrix<sup>8</sup>.

### **Biological enhancement of bone implant fixation**

Bone healing can be stimulated by three different mechanisms: Osteogenesis, osteoinduction, and osteoconduction<sup>52;113</sup>.

**Osteogenesis** promotes local bone formation. Osteogenesis occurs when cells from either autogenous bone-marrow graft, or from autogenous or allogenic bone grafts remain viable to produce new bone at the site of transplantation. Autogenous bone marrow has been successfully applied to enhance bone ingrowth to implants<sup>209</sup>. Furthermore, calcium phosphate coatings are hypothesized to stimulate osteogenesis by releasing nonorganic mineral ions, which activate cellular processes during bone formation<sup>189</sup>.

**Osteoinduction** is new bone formation by mitogenesis of undifferentiated perivascular mesenchymal cells, leading to the formation of osteoprogenitor cells and osteoblasts. Only osteoinductive factors are able to induce extraskeletal formation of bone with a true histological appearance. TGF- $\beta$  and BMPs from the TGF- $\beta$  super family, and bone precursor cells are known to be osteoinductive. Additionally, autografts are osteoinductive as BMPs are released from the extracellular bone matrix as autografts are being resorbed. Experimentally, TGF- $\beta$  adsorbed onto Ca-P coated implants has increased bone ingrowth<sup>109;110;186</sup>, peri-implant bone remodeling<sup>107</sup> and mechanical fixation of implants<sup>109;110;111</sup>. Other experimental studies have applied OP-1 device, which is BMP-7 delivered in a collagen carrier, to

cementless implants<sup>88;108;112</sup>. OP-1 device enhanced fixation of implants inserted with a gap to surrounding cancellous bone<sup>112</sup> whereas only a moderate effect on bone healing was found when OP-1 device was combined with impacted allograft around HA coated implants<sup>108</sup>. Furthermore, OP-1 accelerated resorption of bone allograft and enhanced new bone formation around implants grafted with allograft<sup>88</sup>. Autologous growth factors are also present in blood platelets. Platelet rich plasma has enhanced incorporation of bone autograft<sup>124</sup>, and autologous platelet concentrate (AGF®) in combination with bone allograft has enhanced fixation of non-weight-bearing implants when compared with bone allograft alone<sup>89</sup>.

**Osteoconduction** is enhanced bone formation due to a favorable structural environment, where the osteoconductive material serves as a passive scaffold onto which bone is formed. Auto- and allograft in addition to porous-coated and Ca-P coated implant surfaces are osteoconductive. For auto- and allografts osteoconduction eventually leads to total or partial resorption of the graft and replacement by new host bone. This process is known as creeping substitution<sup>113</sup>. Thus, autograft has the capacity to stimulate bone healing both by osteogenesis, osteoinduction and osteoconduction. Enhanced bone ingrowth and implant fixation have been demonstrated for cementless implants grafted with autograft<sup>97;196</sup>.

In addition to stimulative treatments on bone healing, *antiresorptive* drugs have been applied to enhance implant fixation. Bisphosphonates, which are used clinically for osteoporosis, bind to bone surfaces. During resorption of bone by osteoclasts, the ingestion of bisphosphonate impairs osteoclast function and ultimately causes apoptosis<sup>159</sup>. Resorption of bone allograft pretreated with bisphosphonate has been prevented after 6 weeks compared with almost total resorption of untreated allograft<sup>4</sup>, and micromotion induced peri-implant bone resorption has been reduced by subcutaneously injections of high doses of bisphosphonate<sup>5</sup>. Fixation of implants subjected to micromotion has been increased by oral administration of bisphosphonates; however, surgically stabilizing the implant improved the mechanical properties of the bone implant interface five-fold more than bisphosphonate treatment<sup>11</sup>. Additionally, bisphosphonates have

been successfully applied in animal models for prevention<sup>162;171</sup> and treatment<sup>128</sup> of particle-induced osteolysis. In a prospective, randomized, double blinded study, bone loss due to stress shielding was significantly reduced 6 months after THR for patients given a single systemic infusion of bisphosphonate when compared with patients given placebo<sup>204</sup>. Local treatment of implants with bisphosphonates in canines has also increased bone implant contact after 12 weeks compared with non-treated implants<sup>210</sup>.



## Surgical technique

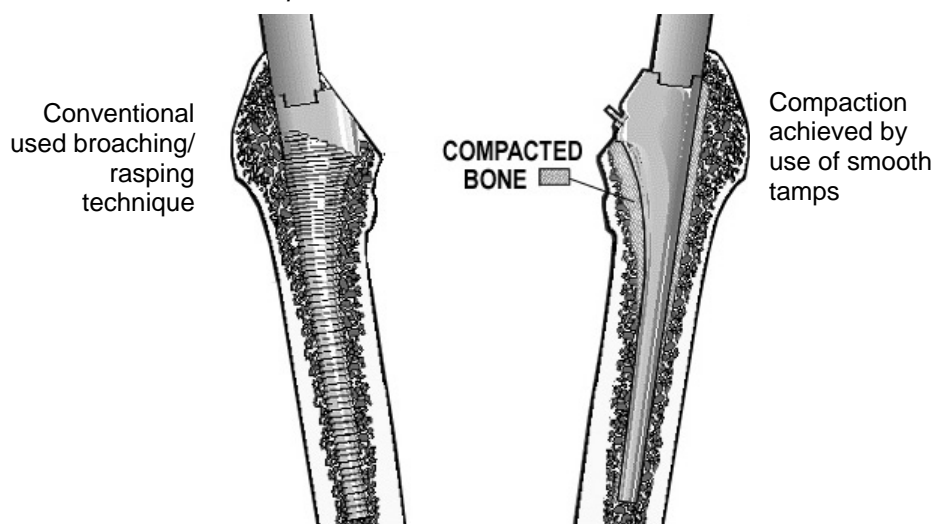
Experimental studies on cementless implants have shown that initial implant fixation is crucial for bone ingrowth<sup>18;22;51;77;85;148;181</sup>. Hence, the initial implant stability created during surgery is of utmost importance for the secondary stability achieved by bony ingrowth. Increased implant stability as a result of insertion with a tight-fit technique has been demonstrated *in vitro*<sup>139;185;202</sup>, *in vivo*<sup>27;179</sup>, and in a finite element analysis<sup>152</sup>. If close apposition between the proximal part of the femoral stem and bone is not achieved, proximal bone loss due to stress shielding might occur as the weight-load and stresses are distributed through the femoral stem and thus by-passes the proximal femur. However, initial direct apposition between implant and bone is often limited to relatively small areas in femoral<sup>146;165</sup> and acetabular components<sup>98;103;117;118;169</sup> due to imprecise reaming techniques, and interindividual variability in bone geometry<sup>136</sup>. The accuracy of acetabular cup implantation has been improved using surgical navigation<sup>74;133</sup>. Robot-assisted surgery has improved accuracy of bone preparation<sup>55</sup>; bone implant contact *in vitro*<sup>123;146;198</sup>; and clinically produced radiographically superior implant fit and fill while reducing the risk of intraoperative femoral fracture<sup>7</sup>. However, the *in vitro* stability of implants inserted into robotically-milled bone cavities depends on the stem design. Out of seven different implant designs inserted either into hand-

broached or robotically-milled femora, three stem designs were more stable in hand-broached femora, and only three stem designs were more stable in femora prepared with robots<sup>191</sup>. No controlled clinical studies have demonstrated improved success rates for THR with either robot-assisted surgery or surgical navigation. Custom made prostheses fabricated from a CT scan, allowing three dimensional specifications of femoral anatomy, have been introduced to enhance fit and fill of variable hip geometry. However, conflicting clinical data exist on whether custom made prostheses can improve success rates for THR<sup>6;13;137</sup>. In addition, the aggregate economic charge of manufacturing a custom made prosthesis, and the necessity of a preoperative CT scan, might dictate the use of “off the shelf” prostheses in primary THR<sup>125</sup>.

### Bone compaction

A new surgical technique preparing the bone cavity for implantation by compaction of existing cancellous bone has recently been shown to increase initial implant fixation<sup>32-34;67;211</sup>. In THR, the compaction technique sequentially expands existing cancellous bone using increasing sizes of smooth tamps<sup>34</sup> in contrast to conventionally used rasping/broaching techniques where cancellous bone is partly removed during preparation of the bone cavity (Figure 1).

**Figure 1.** Instruments with a toothed or smooth surface used for preparation of the femur prior to insertion of a femoral stem



**Table 1.**

Comparison between bone compaction and bone extraction techniques (drilling, broaching, and rasping).

<i>Authors</i>	<i>Surgical application</i>	<i>Model</i>	<i>Results</i>
Channer et al, 1996 <sup>32</sup>	Cementless TKR	<i>In vitro</i> ; human tibia	Increased tibial stem stability with compaction compared with press-fit
Green et al, 1999 <sup>67</sup>	Non-weight-bearing stainless steel porous coated implants inserted exact-fit	<i>In vivo</i> ; canine humerus	Increased pull-out stiffness at 0, 3, 6 weeks and increased ultimate load at 0 and 3 weeks with compaction compared with conventional drilling. No difference in mechanical fixation at 9 weeks. Increased peri-implant bone density at 3 weeks, but not at 9 weeks. No difference in bone ingrowth at any time period.
Chareancholvanich et al, 1999 <sup>33</sup>	Weight-bearing Ti implants inserted exact-fit	<i>In vivo</i> ; canine femur	Increased interfacial shear strength with compaction compared with drilling (pooled data from 2 and 4 weeks)
Yu et al, 1999 <sup>211</sup>	Cementless THR	<i>In vitro</i> ; human femur	Increased fixation stiffness; decreased subsidence; and increased periprosthetic bone density (evaluated by QCT) of femoral stems inserted with compaction compared with rasping.
Vail et al, 2000 <sup>197</sup>	Non-weight-bearing HA coated implants with a smooth surface texture inserted exact-fit	<i>In vivo</i> ; rabbit femur	No difference in pull-out force after 12 weeks between compaction, rasping and drilling.
Breusch et al, 2001 <sup>20</sup>	Cemented THR	<i>In vitro</i> ; human femur	Fractures in 6 of 9 femora prepared with smooth tamps compared with no fractures in 9 femora prepared with chipped-tooth broaches.
Chareancholvanich et al, 2002 <sup>34</sup>	Cementless and cemented THR	<i>In vitro</i> ; human femur	Less femoral stem micromotion with compaction compared with extraction broaching.
Kold et al, 2002 <sup>(I)</sup>	Cemented THR	<i>In vitro</i> ; human femur	At preoperative templated size, fractures in 8 of 10 femora prepared with smooth tamps compared with fractures in 2 of 10 femora prepared with toothed broaches.
Kold et al, 2002 <sup>(II)</sup>	Cementless THR	<i>In vitro</i> ; human femur	At preoperative templated size, fractures in 2 of 10 femora prepared with compaction compared with no fractures in 10 femora prepared with rasping.
Kold et al, 2002 <sup>(III)</sup>	Weight-bearing Ti implants inserted exact-fit	<i>In vivo</i> ; canine femur	Increased ultimate shear strength and energy absorption with compaction at 0 and 4 weeks, but not at 2 weeks, compared with drilling. Increased bone implant contact and peri-implant bone density with compaction at 0 and 2 weeks, but not at 4 weeks.
Kold et al, 2002 <sup>(IV)</sup>	Weight-bearing HA implants inserted press-fit	<i>In vivo</i> ; canine femur	Increased ultimate shear strength with compaction at 0 and 2 weeks, but not at 4 weeks, compared with drilling. Increased energy absorption, and bone implant contact with compaction at time 0, but not at 2 and 4 weeks. No significant difference in peri-implant density between compaction and drilling at 0, 2 or 4 weeks.
Kold et al, 2002 <sup>(V)</sup>	Implantation cavities in cancellous bone	<i>In vivo</i> ; canine femur	Smaller post-operative equivalent circle diameter of compacted cavities compared with drilled cavities, even though cavities initially had been prepared to identical dimensions.

A list of publications comparing bone compaction with bone removing procedures in bone implant research is presented in table 1.

Bone compaction was first used in an experimental *in vitro* study of cementless TKR in 1996 by Channer et al.<sup>32</sup>. They demonstrated that stability of cementless tibial stems inserted with compaction was in average 85% greater than stems inserted with conventional press-fit. Bone compaction for THR has been compared with conventional broaching and rasping in human cadaver femurs<sup>20;34;211</sup>. Compaction increased fixation stiffness, and periprosthetic bone density measured by QCT of cementless femoral stems<sup>211</sup>. Furthermore, compaction reduced micromotion and subsidence of femoral stems<sup>34;211</sup>. Breush et al.<sup>20</sup> compared polished tamps for compaction of cancellous bone with conventional used chipped-tooth broaches in 9 pairs of femurs. They found no difference in cement penetration between femurs prepared with compaction or broaching; however, fractures occurred in 6 of 9 femora prepared with smooth tamps compared with no fractures in the corresponding 9 femurs prepared with chipped-tooth broaches. This study raises concerns about an increased risk of femoral fracture with compaction even though the impact procedures of the different instruments were not standardized,

Green et al.<sup>67</sup> used pull-out test and quantitative histology to compare the effects of compaction and drilling on non-weight-bearing stainless steel porous-coated implants in the proximal metaphysis of the canine humerus. Compaction significantly increased fixation stiffness at 0, 3 and 6 weeks, and ultimate fixation strength at 0 and 3 weeks; however, there was no significant difference in either fixation value at 9 weeks. Histology revealed increased peri-implant bone density at 3 weeks, but not at 6 weeks. No difference in bone ingrowth was found. Another canine study using weight-bearing porous coated Ti implants demonstrated increased mechanical fixation with compaction compared with drilling; however, the data from two different observation periods (2 and 4 weeks) were pooled, and no histological data were

reported<sup>33</sup>. In the rabbit no significant differences in pull-out force were found after 12 weeks between non-weight-bearing HA coated implants inserted either with compaction, rasping or drilling<sup>197</sup>.

No clinical studies comparing compaction with conventional preparation techniques on the outcome of THR are available. However, instrumentation for insertion of femoral stems with bone compaction or bone compression is currently marketed. This is of great concern as questions about bone compaction for THR still remain, and systematic design evaluation, pre-clinical testing and clinical trials must be performed before introducing new implantation techniques<sup>82</sup>.

## **Biomaterials**

Metals used for cementless THR must fulfill conflicting needs. The metal must exhibit strong mechanical properties; however, the elastic modulus of the metal should resemble that of human cortical bone in order to avoid stress-shielding. The metal must also be resistant to corrosion, and at the same time be highly biocompatible. It seems that the metal best fulfilling the needs for cementless THR at the moment is Ti-6Al-4V<sup>76</sup>. However, in a recent randomized study using RSA and DEXA, a femoral stem (Epoch) with a reduced stiffness has shown encouraging short-term results after two years with excellent primary fixation, and decreased proximal bone loss compared with a stiffer stem<sup>93</sup>. The Epoch stem has a central core made of forged cobalt-chromium alloy which is covered by a metal mesh made of commercially pure titanium. Solid metals, such as stainless steel and cobalt-chrome, are also used for orthopaedic implants.

### **Porous-coated implants**

Implants used for cementless THR are often roughened by various techniques, such as grit-blasting, etching or by coating, in order to increase the implant surface for bone ingrowth. Additionally, increased platelet adhesion and increased platelet activities have been found on roughened implants compared with smooth implants<sup>145</sup>. Coated implants are implants with an additional layer of material added on the surface, typically consisting of a porous metal structure and/or a calcium phosphate layer. The term porous refers to interconnecting channels (pores) with osteoconductive properties on the implant surface. The optimal pore size for ingrowth of bone is between 50 and 400  $\mu\text{m}$ <sup>15</sup>. Implants used in the current studies had the porous structure applied to the implant by a plasma spraying technique. Other techniques for implant coating are sintering technique and diffusion bonding.

### **Hydroxyapatite**

Substantial experimental and clinical data in favor of HA coated implants exist. Experimentally, it has been demonstrated by de Groot et al. and others<sup>44;46;62</sup> that plasma sprayed HA coated implants enhance mechanical fixation of implants inserted with press-fit compared with uncoated implants. Søballe et al. have shown that HA coating also is capable of enhancing bone ingrowth and mechanical fixation of implants inserted with an initial gap to surrounding bone during stable and unstable mechanical conditions<sup>174;176;178;179;181</sup>. Furthermore Søballe et al. demonstrated that HA coating had the ability to bridge the peri-implant gap by bi-directional bone growth both with and without the presence of bone allograft in the gap<sup>178;180</sup>. Overgaard et al. have documented the importance of applying HA coating to porous-coated implants instead of grit-blasted implants<sup>142</sup>. Macroscopic evaluation of the surface after push-out testing revealed that grit-blasted implants had pronounced delamination of the HA coating in contrast to porous-coated implants, indicating that the bonding strength of HA on porous-coated implants was greater. Rahbek et al. demonstrated reduced peri-implant migration of polyethylene particles due to sealing effect of HA coated implants<sup>150;151</sup>. Clinically, six of seven randomized studies using RSA have documented less initial migration of HA coated femoral hip and tibial knee components<sup>95;135;138;154;182;192</sup>; in only one randomized study no difference in migration of HA and non-HA coated implants was detected<sup>38</sup>. Human retrievals of HA coated implants have documented good bone apposition suggesting stability between implant and bone<sup>9;10;43;175;194</sup>. Coathup et al.<sup>40</sup> compared ingrowth of bone to 21 stems of similar designs retrieved post mortem, matched according to their length of time *in vivo*. Porous HA surfaced implants had superior bone ingrowth and bone grew more evenly over the surface compared with plain porous and interlock implants.

## **Aims of experimental studies**

The aim of the present experimental studies was to evaluate potential complications and improvements with bone compaction. Thus, the present studies together with already conducted studies should provide information for a decision to be made whether compaction should be further studied in prospective, randomized clinical studies.

### **Risk of femoral fracture with compaction**

Little is known as to whether the risk of intraoperative femoral fracture is increased by preparation of the femoral canal using smooth tamps. Conventional toothed broaches and rasps should, theoretically, be able to cut and remove bone when they are driven into the femoral canal, whereas smooth tamps neither cut nor remove bone but rather displace and compact bone. Therefore, smooth tamps may lead to higher hoop stresses in the femur than those produced by toothed broaches or rasps. Thus, preparation of the femoral canal with smooth tamps might involve a greater risk of femoral fracture than preparation with conventional toothed broaches or rasps.

*The risk of femoral fracture with compaction versus broaching using instrumentation for cemented THR was evaluated on cadaver femurs in a controlled in vitro drop tower model (I).*

*Using the experiences from study I, instrumentation for compaction in cementless THR was developed. The risk of femoral fracture with compaction versus rasping using this new instrumentation was evaluated on cadaver femurs in the controlled in vitro drop tower model (II).*

The surgeon might become alert of an impending femoral fracture if an increasing force is needed to maintain the downward progression of the tamp.

*For the femurs that were prepared with tamps the force applied at fracture was compared with the initial applied force (I, II).*

### **Effect of surgical technique on preoperative to postoperative BMD evaluated by DEXA**

DEXA is used clinically to follow changes in periprosthetic BMD after THR<sup>100;161;187;203;204</sup>. Additionally, the immediate effects of arthroplasty

surgery on periprosthetic BMD have been detected by comparing immediate postoperative DEXA scans with preoperative DEXA scans from the ipsilateral femur<sup>102</sup>. Dependent on the applied surgical technique immediate postoperative BMD decreases<sup>102</sup> and increases<sup>35</sup>, as well as no effects of the surgery<sup>187</sup> have been detected in the proximal medial femoral zones after THR. Compaction has been shown to increase preoperative to postoperative periprosthetic bone density when evaluated by QCT<sup>211</sup>. However, clinically, it is preferable if DEXA can be used to detect preoperative to postoperative BMD changes as DEXA exhibits considerable less radiation than QCT.

*It was investigated whether single pass advancements of smooth tamps would increase the periprosthetic BMD of cadaver femurs evaluated by DEXA (I). Furthermore, the changes in preoperative to postoperative BMD was compared between single pass advancements of smooth tamps and single pass advancement of toothed broaches (I).*

### **Effect of surgical technique on fixation of weight-bearing implants**

The effects of compaction versus drilling have been examined *in vivo* using non-weight-bearing implants<sup>67;197</sup>. However, because joint replacements are weight-loaded, it is important to test new surgical techniques *in vivo* using weight-bearing implants as different implantation techniques have exhibited different responses during loaded and unloaded conditions<sup>132</sup>.

*The effects of compaction versus drilling on mechanical fixation and on bone implant contact were evaluated in a weight-bearing, intra-articular canine model after 0, 2 and 4 weeks using exact-fit insertion of Ti implants (III), and press-fit insertion of HA implants (IV).*

### **Spring-back effect of compacted bone**

It has been proposed that the enhanced implant fixation found with compaction might be explained by a spring-back effect of the visco-elastic cancellous bone<sup>67</sup>(III, IV). However, compaction might damage the structure of cancellous bone to

such an extent that no spring-back of compacted bone occurs, and a spring-back effect of compacted bone is yet to be proven.

*The postoperative equivalent circle diameters of implantation cavities prepared in vivo with compaction or drilling were compared using micro-CT scanning (V).*

## **Methodological considerations**

### **Experimental subjects**

Linde et al. have demonstrated that changes in mechanical properties of cancellous bone occur immediately post mortem<sup>115</sup>. They found a ten percent decrease in compression stiffness of cancellous bone during the first 24 hours post mortem. Further long term storage by freezing or ethanol did not change the stiffness, and neither did several thawing, testing and refreezing sequences; however, the viscoelastic properties showed significant changes during long term storage. This demonstrates that it is preferable to compare the effects of different surgical techniques *in vivo*. We used *in vivo* bone to examine a possible spring-back effect of compacted bone (V) and to evaluate the effects of compaction on implant fixation after 2 and 4 weeks of weight-bearing conditions (III, IV). However, fresh frozen *in vitro* bone were used to represent time 0 in study III and IV. The use of *in vitro* bone at time 0 might have reduced the differences in implant fixation between compaction and drilling as the compaction technique seems to benefit from the visco-elastic properties of cancellous bone (V). In the studies on the risk of femoral fracture (I, II) using instrumentation for THR, we found it important to use human femurs, and due to ethical considerations we used *in vitro* bone.

The most common indication for THR is osteoarthritis<sup>116</sup>. The quality of arthrotic cancellous bone is deteriorated with reduced mechanical properties despite a higher bone volume fraction compared with non-arthrotic cancellous bone<sup>49</sup>. Thus, it would be preferable to use specimens with arthrosis to resemble the clinical situation. However, in the present studies only some of the cadaver femurs and none of the dogs had radiologically or macroscopically signs of osteoarthritis.

### **Cadaver femurs**

*In vitro* research of intraoperative femoral fracture have used both fresh frozen<sup>26</sup> and embalmed<sup>83</sup>

human cadaver femurs. We used fresh frozen cadaver femurs as the embalming process decreases the measured fracture energy of bone<sup>149</sup>.

### **Animals**

In basic bone-implant research, animal models are used to obtain samples after predetermined observation periods. In addition, the animal model has some advantages compared with clinical trials in humans. The animals are more genetically alike because of inbreeding, which results in less biological variance. Furthermore, the animal can serve as its own control. The most commonly used animals in bone-implant research are rats, rabbits, sheep, dogs, and monkeys. The dog was chosen as the experimental animal for biological and practical reasons. Biologically, Aerssens et al. have compared bone composition, density and quality between bone samples derived from human, dog, pig, cow, sheep and rat<sup>1</sup>. They found that the characteristics of human bone are best approximated by the properties of dog bone. However, experiments in animals obviously cannot replace human studies, and several limitations from results in animals are present as well. The present animal studies were done in healthy bone, and the remodeling rate of dog bone is 2-3 times higher than in healthy humans<sup>99</sup>. Practically, we had to use implants of a certain size to obtain sufficient samples for mechanical testing and histomorphometry. Dogs weighing more than 20 kg do have appropriately sized femoral condyles for implant insertion into cancellous bone. Finally, at our institution we have extensive experience in using dogs in bone-implant research, and thus, we have important information available for choosing relevant observation periods.

### **Ethical considerations**

All femurs were obtained with the appropriate informed consent of the donor or donor next-of-kind, in compliance with all U.S. applicable local, state and federal laws and regulations governing the retrieval, supply and disposal of human tissue. Animal studies were approved by the Danish

Control Board for Animal Research, and the Animal Care and Use Committee of the Minneapolis Medical Research Foundation, Minnesota, USA. The dogs were bred for scientific purposes and treated in compliance with Danish and American laws for the use of experimental animals.

### Design of studies

In all studies we used a paired design where each individual served as its own control. In the basic *in vivo* study (V) investigating a spring-back effect, it was assumed that no preoperative differences in bone quality existed between left and right legs. Thus, cavities in the right lateral femoral condyles were prepared by compaction, and cavities in the left lateral femoral condyles by drilling. In all other studies (I-IV), one side was randomized to compaction, and the other side to the conventional bone removing technique (broaching, rasping or drilling). In the studies examining implant fixation, implants, that represented time 0, were inserted into lateral femoral condyles. To reduce the number of animals used, the same dogs as used for 2 and 4 weeks' observation periods in study III were also used in study IV. In study III, Ti implants were inserted with exact-fit either into both medial femoral condyles or into both lateral femoral condyles. In study IV, HA implants were inserted with press-fit into both medial femoral condyles or into both lateral femoral condyles. The bias from differences in weight-bearing pattern and in bone repair rate between right/left and medial/lateral location was thus eliminated.

#### Sample size

The risk of making a type I error (two-sided  $\alpha$ ), i.e., concluding that the two sides were different when, in fact, no difference existed, was set to 5%. The risk of making a type II error ( $\beta$ ), i.e., concluding that the two sides were the same when, in fact, a difference existed, was chosen to be 20%. Thus, the power ( $1 - \beta$ ) of the experiments was set to 80%.

In the fracture studies (I, II) binominal data (+/- fracture) were studied, and the sample sizes were

calculated by use of statistical software (NCC PASS 2000, Dawson Edition). The proportional discordant, i.e., the proportion of femoral pairs having a fracture at only one side, was set to 80%. The odds ratio for femoral fracture between compaction and the conventional used technique was set to 25. Based on these assumptions, at least 10 pairs of femurs should be included in each experiment.

In the dog studies continuous paired data were studied (III-V), and the sample sizes were calculated from a normogram for continuous paired data<sup>2</sup>. The minimal clinically relevant difference was set to 55%, and the standard deviation of the expected changes was set to 50%. Based on these assumptions, at least seven experimental subjects should be included in each experiment. Eight dogs were included for each observation period in study III, and for each of the 2 and 4 weeks observation periods in study IV. Seven dogs were included in study V, and for time 0 in study IV.

### Surgical techniques and instrumentation

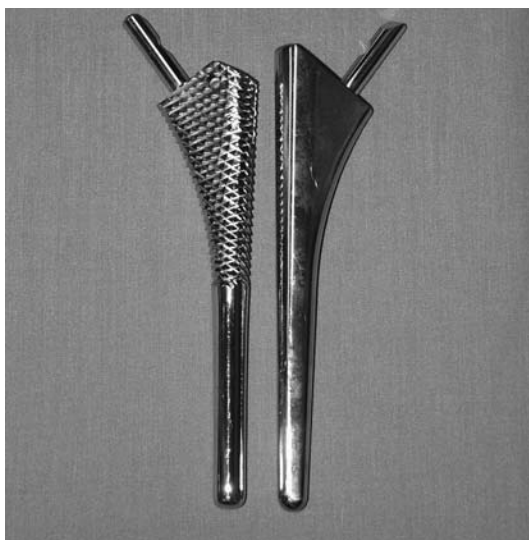
*Study I* was designed to examine whether a difference in femoral fracture risk existed between the uses of smooth tamps and toothed broaches when all other surgical procedures were identically performed. Thus all femurs were reamed distally by a flexible reamer, and no initial bone was removed by a block-chisel. When conducting study I, the only instrumentation available for femur preparation with smooth tamps was instrumentation for a cemented primary THR (Prime Cemented Hip System, Orthopaedic Innovations Inc, Golden Valley, MN, USA). The broaches had a toothed surface and the tamps had a smooth surface (Figure 1). For each broach size, the corresponding tamp size had the same base volume as the toothed broach without the teeth. The smooth tamps and the toothed broaches were advanced into the femoral canal in single passes, without alternating between a distal and a proximal motion. The single pass method to advance a broach has been recommended for cementless



technique<sup>23</sup>. However, under surgical conditions, the broaches often are impacted alternatively and withdrawn. Repeated withdrawal allows bone to be removed from the femoral canal, and also may prepare the femur imperfectly<sup>23</sup> because slight changes in orientation during repositioning of the instrument could lead to a less tight fit of the femoral implant. Tamps are usually advanced in single pass motions. Bone has viscoelastic properties, and therefore the rhythm by which an instrument is advanced into the medullary canal could be expected to have an effect on the risk of femoral fracture. To be able to compare smooth tamps with toothed broaches it was important to advance both types of instruments in single passes with impacts applied in similar rhythms. By using single pass advancement, the differences in the risk of femoral fracture between the clinically used broaching technique (alternating between a distal and a proximal motion) and the clinically used tamping technique (single pass motion) might have been underestimated. Additionally, it might be that the applied single pass broaching technique preserves more bone than the clinically used broaching technique alternating between a proximal and distal motion. Thus, the difference in preoperative to postoperative BMD changes between tamped and broached femora might have

**Figure 2.**

*The two different instrument configurations used in study II: diamond shaped rasps (left) and smooth tamps (right). Note the proximal lateral tip which is only present on the smooth tamp.*

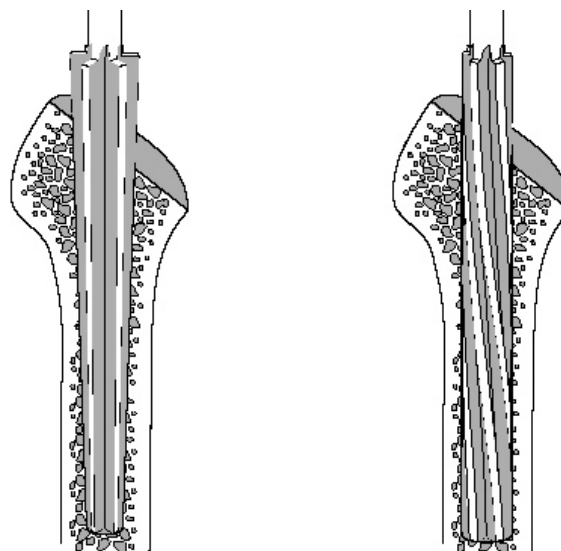


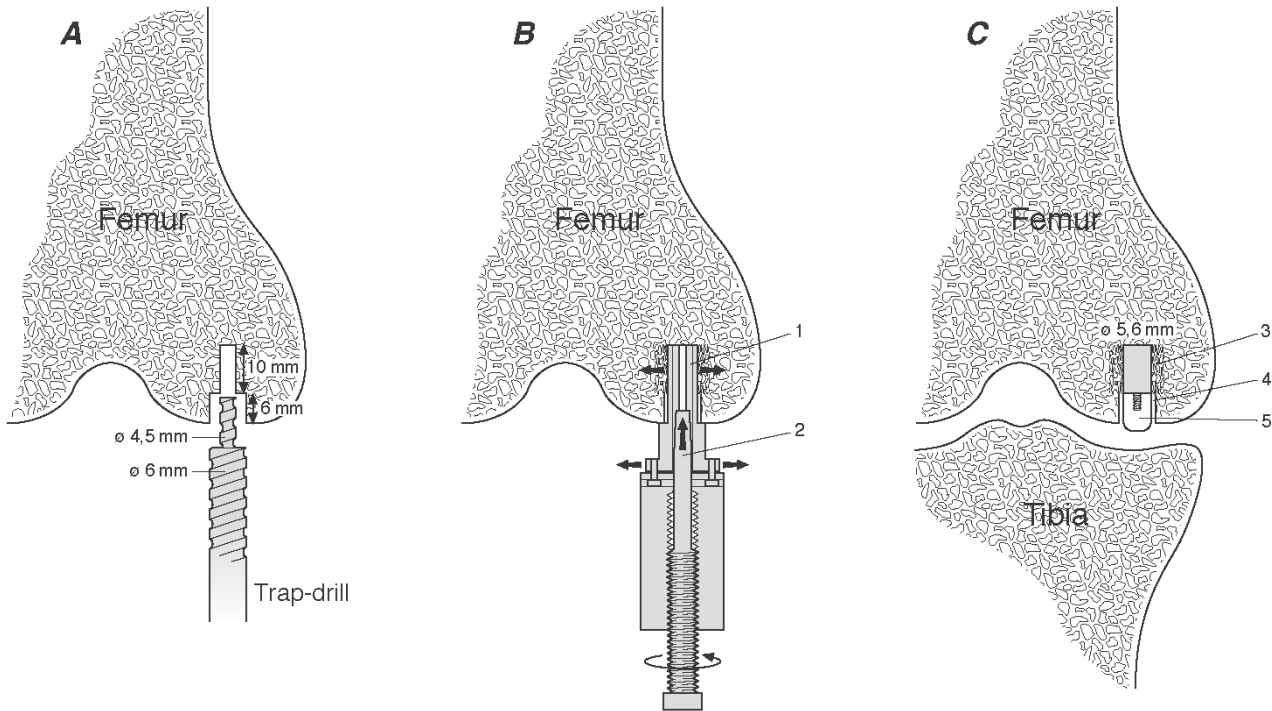
been underestimated compared with the clinical situation.

*Study II* was designed to examine whether a difference in femoral fracture risk existed between the standard rasping technique and the compaction technique using newly developed instrumentation for a cementless primary femoral stem (Bi-Metric Hip, Biomet Inc, Warsaw, IN, USA). The upper half of the rasps had a diamond shaped surface with the remaining distal part having a smooth surface. The tamps had only a smooth surface. For each rasp size, the corresponding tamp size had the same base volume as the rasps without the teeth, except that the tamps had a proximal lateral extension which the rasps did not have (Figure 2). The compaction procedure included distal reaming with cylindrical reamers (Figure 3), and proximal bone preparation with smooth tamps of increasing sizes. The conventional rasping procedure was performed in accordance with the suggestions by the manufacturer of the instruments, and thus included distal reaming with conical shaped reamers (Figure 3), and proximal bone preparation with toothed rasps of increasing sizes. For each twenty impacts, the instruments were withdrawn and cleaned for bone debris. The withdrawal allowed the bone, which had been cut by the toothed rasps, to be removed from the femoral canal.

**Figure 3.**

*Initial reaming in study II. Left side: Conical reamer used together with toothed rasps for the rasping procedure. Right side: Cylindrical reamer used together with smooth tamps for the compaction procedure.*



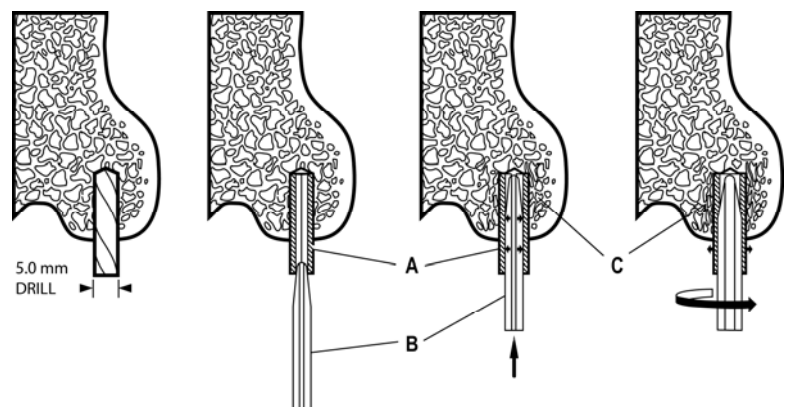


**Figure 4.** The compaction procedure used in study III and IV. A) Initially, a 4.5 mm x 10 mm deep cavity, and a 6.0 mm x 6 mm superficial cavity is drilled. B) A special designed bone compactor expands radially the cancellous bone in the deep cavity. The lips (1) are incrementally split apart by increasing sizes of screws (2) until the deep part of the cavity reaches a diameter of 5.6 mm. The compactor is turned 360 degrees to ensure compaction of cancellous bone around the entire periphery of the hole. C) Ti implant inserted into compacted cavity (3). A 200  $\mu$ m gap (4) surrounds the polyethylene plug (5) to allow access of joint fluid to the bone implant interface, and to ensure that the polyethylene plug does not influence initial implant fixation. During weight-bearing the load is transferred through the polyethylene plug from the tibial plateau to the test implant.

*Study III, IV and V.* In the animal studies, compaction was compared with drilling, which represented the conventional bone removing technique. All cavities were prepared to a diameter of 5.6 mm. For the drilling groups these cavities were created by a 5.6 mm drill. For the compaction groups the cavities were created by radially expanding either a 4.5 mm pilot drill hole to 5.6 mm (III, IV) (Figure 4) or a 5.0 mm pilot drill hole to 5.6 mm (V) (Figure 5). Study III examined the basic effects of compaction versus drilling on the

fixation of Ti implants during weight-bearing conditions, and therefore the implants in study III were inserted with exact-fit. Study IV examined the effects of compaction versus drilling during optimal implant conditions. Thus, the implants in study IV were coated with HA and were inserted with press-fit. Due to differences both in implant characteristics (Ti versus HA) and in surgical techniques (exact-fit versus press-fit) between study III and IV, no comparisons were made between data from study III and IV.

**Figure 5.** The compaction procedure used in study V. Initially a 5.0 diameter pilot hole was drilled. Then increasing sizes of split rings (A) were inserted into the hole, and a finned tool (B) was driven into it to compact the cancellous bone (C). Finally, the entire tool was turned 360° to compact the cancellous bone around the entire periphery of the hole. Compaction was done until the diameter of the hole was 5.6 mm.



## IN VITRO MODEL (I, II)

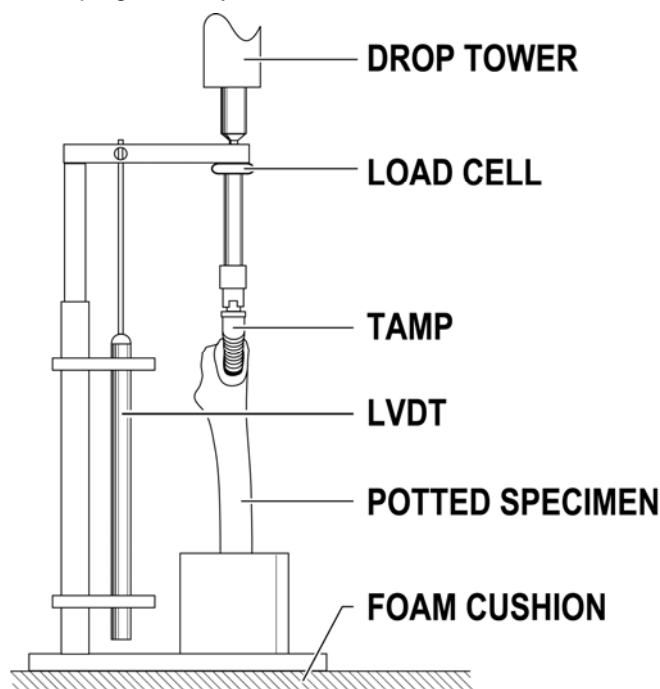
### Preoperative templating

The femoral fracture risk at different instrument sizes was expressed in relation to preoperative templated size. Standardized AP and lateral preoperative radiographs were taken of each femur with a 10-cm marker parallel to the femur, and the exact magnification of the femurs on the radiographs was calculated. Then templates were made with the exact same magnification as the femurs, and standard preoperative templating was done. From preoperative templating, the level of the neck cut was standardized. In study II, the preoperative templating was also used to determine the maximum instrument size to be inserted. The accuracy of preoperative templating approaches 100% when cementless femoral prostheses within two sizes above or below the templated size are used<sup>29</sup>. Therefore the maximum instrument size that was inserted in study II was two sizes above preoperative templated size.

### Experimental *in vitro* fracture model

We used a drop tower to control the initial applied forces and the increments in forces needed for advancing tamps, broaches and rasps into the cadaver femurs (Figure 6). Other *in vitro* studies on femoral fracture in THR have used a servohydraulic materials testing system<sup>26;83</sup>, which advances the instrument under displacement control. However, the smooth progression of the instrument at a constant displacement rate with the materials testing system does not resemble a clinically relevant impact protocol. Because bone is viscoelastic<sup>114</sup> the risk of femoral fracture is dependent not only on the applied force but also on the applied impulse (force over time). The drop tower was set-up to mimic the impulse generated clinically when a broach, a rasp or a tamp is driven into the femur. Thus, an experienced orthopaedic surgeon, who had been using the tamping technique clinically, hit with a hammer onto a steel block in a similar way as he would do when advancing a broach or a tamp into a femoral canal.

**Figure 6.** The experimental set-up used in study I and II. The instrument is driven into the femur by use of a drop tower. A load cell records the applied force, and a linear variable displacement transducer (LVDT) measures the displacement of the instrument. A foam cushion underneath the potted specimen provides damping to the system.



For each blow the force versus time was recorded by a high frequency load cell (range, 22240 N; frequency of data capture 25,000 Hz; Kistler Inc, Winterthur, Switzerland), and a force versus time curve of the impact was generated (LabView, National Instruments, Austin, TX, USA). From these data the drop tower was set-up so the force over time curve generated, when a falling weight hit the steel block, mimicked the curve generated by the surgeon's hit. Thus the initial applied force to the tamp, broach or rasp came from dropping an aluminum weight (0.7 kg) from 13 cm height in a drop tower of the same nominal diameter as the cylindrical weight.

When the displacement of the instruments, as measured by a linear variable displacement transducer (Lucas Schaevitz Inc, Pennsauken, NJ, USA; full range, 10.2 cm) (Figure 6), became less than 0.2 mm for 10 successive impacts (I) or less than 0.2 mm for 5 successive implants (II), the applied force was incrementally increased. As

many as seven (II) or eight (I) successive increments were performed. The increments in force were achieved by raising the height of the falling weight in increments from 13 cm to 28 cm, and by using a steel weight (1.4 kg).

For each blow, the maximum force was identified (LabView, National Instruments, Austin, TX, USA). The recorded forces are reported separately for study I and II as they are dependent on the shape and size of the instrument relative to the shape of the femoral canal. For study I, the mean initial applied force was 3017 N (SD, 381 N), and the mean increment in force of the eight successive increments was 15% (SD, 12%). For study II, the mean initial applied force was 2531 N (SD, 647 N), and the mean increment in force of the seven successive increments was 16% (SD, 9%).

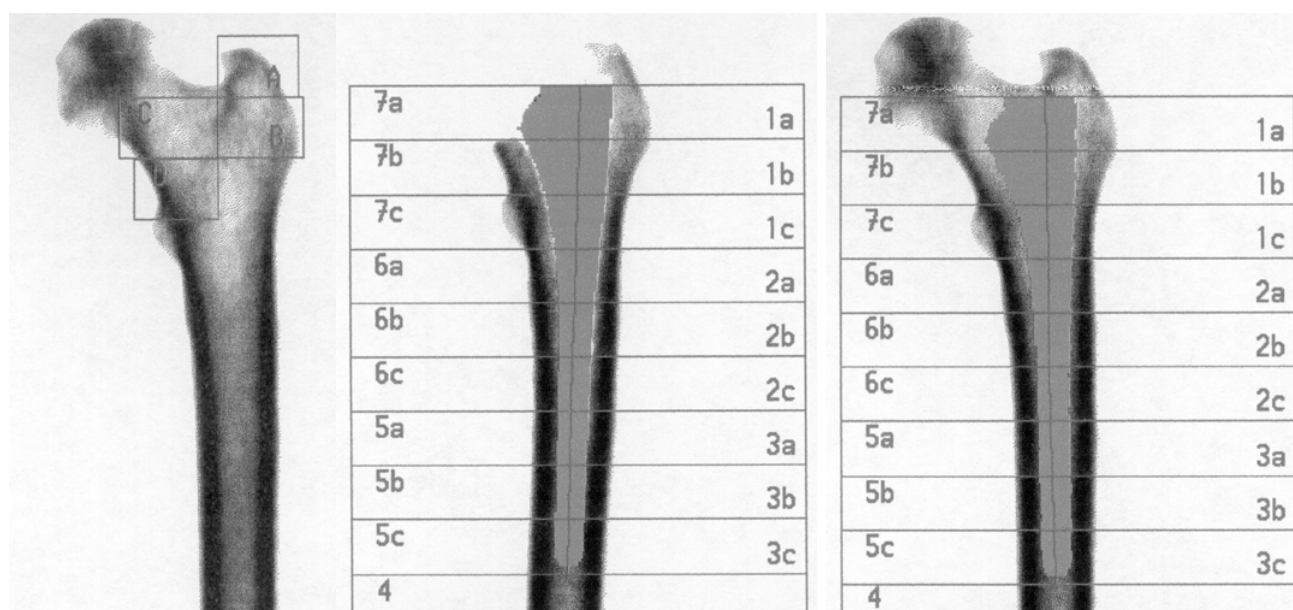
The variances of the forces and of the increments in forces are the sums of the variance attributable to dropping the weight, the variance attributable to measuring the forces, and the variance attributable to differences in absorptive properties of the femurs. Although dropping the weight in the drop tower is a well-controlled procedure, there is some variation inherent in the use of any drop tower. This variation includes variation in the release of the weight and variation in the falling of the weight in the drop tower. Factors that contribute to the variance of measuring the force of impact are the signal from the load cell, and the software processing of the signal from the load cell. However, these factors only contribute little to the total variance because the load cell and data capture equipment are high frequency, and because the peak force detection algorithm is automated and tested to be reliable for the types of curves encountered. We believe that the main contribution to the variance of the measured forces came from the variance in absorptive properties of the femurs when the instruments were impacted into the femurs. Factors that contribute to the variance in absorptive properties of the femurs are: 1) the shape and size of the instrument relative to the shape of the femoral canal because the shape of the instrument matches the shape of the femoral canal

more in some femurs than in others; and 2) the density of the femur.

When a femur is prepared *in vivo*, energy is absorbed passively because of elastic deformation of the soft tissues surrounding the bone<sup>26;41</sup>. Similar to the study of Elias et al.<sup>54</sup>, we used a dense foam pad underneath the bone to represent this damping. However, as the actual surgical setting is more complex, the *in vitro* values for the forces needed to fracture the femurs found in study I and II cannot be transferred directly to the *in vivo* situation. However, the use of paired femurs for controls allows the risk of femoral fracture with compaction to be compared with the risk of femoral fracture with broaching or rasping.

### DEXA scanning

In study I, the femurs were scanned using a Lunar DPX-L bone densitometer (Lunar Corporation, Madison, WI, USA). A 150-mm high water column was placed as soft tissue equivalent above the femurs to prevent the x-ray beam from scanning into air. To examine whether DEXA could detect changes in periprosthetic BMD after single pass advancements of smooth tamps compared with single pass advancements of toothed broaches, the compare function of the Lunar Orthopaedic Software Package (Version 1.2) isolated the instrument from the postoperative scan and superimposed the instrument mask over the preoperative scan (Figure 7). To accomplish the highest precision of the scans, the femurs were potted in square boxes, so the femurs were positioned in the same degree of rotation between successive scans<sup>42;131;173</sup>. The changes in preoperative to postoperative BMD were calculated for the Gruen Zones 7B and 7C<sup>68</sup>, because no reaming had occurred in these medial regions allowing the isolated effects of smooth tamps and toothed broaches to be investigated. DEXA measures BMD averaged over the entire width of cancellous and cortical bone. Thereby, DEXA might not be able to detect small changes in cancellous BMD as these changes might be overpowered by unchanged cortical values. In



**Figure 7.** DEXA scans of a femur from study I. Left: Preoperative scan. Middle: Postoperative scan with the appropriate size instrument in situ. Right: Overlay of the instrument from the postoperative scan into the preoperative scan. The Gruen zones<sup>68</sup> are shown in the scans with the instrument in situ.

contrast, QCT is able to detect isolated changes in cancellous bone<sup>211</sup>, and increases in periprosthetic bone density have been found with QCT after tamping compared with broaching.

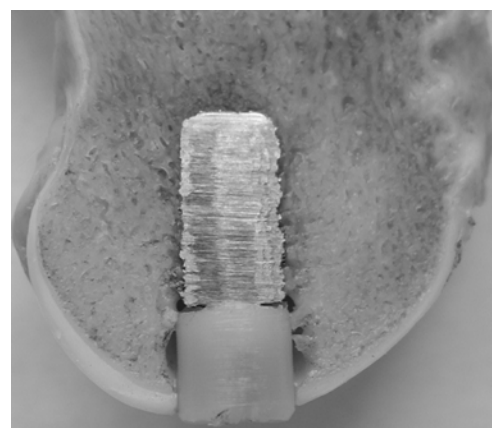
### Evaluation of fracture

In study I, femurs were examined for fractures both by macroscopic inspection and by postoperative AP and lateral radiographs with the final instrument left in situ. In accordance with previous studies that concluded that postoperative radiographs usually are inadequate to show linear undisplaced fractures, particularly with the femoral component in place<sup>84;86</sup>, none of the fractures in study I were detected on postoperative AP or lateral radiographs. Therefore, femoral fractures were only evaluated by macroscopic inspection in study II.

### IN VIVO MODEL (III-V)

#### Experimental animal models

The different surgical techniques were applied in cancellous bone (Figure 8), as primary cementless THR rely on cancellous bone ingrowth.



**Figure 8.** Test implant inserted in cancellous bone. A vertical section (x 2.5) through a femoral condyle from a dog, not included in the presented studies, demonstrating the placement of the implant in cancellous bone.

In study III and IV, the implants were inserted intra-articularly to simulate the clinical situation as joint fluid has access to the bone implant interface<sup>166</sup>. Furthermore, the implants were inserted into a weight-bearing model (Figure 4). It is important to evaluate new surgical techniques in weight-bearing implants as implants in situ do carry very high load, and as different implantation techniques have exhibited different responses during loaded and unloaded conditions<sup>132</sup>. In addition, an increase in cancellous connectivity has been found during mechanical stimulation of bone repair when compared with no mechanical stimulation<sup>69</sup>, and reorientation of trabeculae to achieve maximal mechanical effectiveness occurs during weight-bearing (Wolff's law)<sup>208</sup>. Moreover, it may be particularly important to examine the effects of compacted bone in weight-bearing models. When impacted allograft, an allograft procedure resembling the primary compaction procedure, is applied around cementless tibial stems, it has been shown that the amount of new bone replacing the impacted graft increases with mechanical loading compared with no mechanical loading<sup>200</sup>.

### Observation periods

In study V, the dogs were kept anaesthetized for ten minutes after the surgical procedure allowing sufficient time for a possible spring-back effect of compacted bone to occur before euthanization. In study III and IV, a group at time 0 was included to control that the applied compaction procedure was able to increase initial implant fixation compared with drilling. The *in vivo* observation periods of 2 and 4 weeks represent time periods with ongoing healing and formation of new bone.

The dog has great healing capacities compared with human patients<sup>99</sup>, and all biocompatible implants that are inserted with exact- or press-fit into the dog femoral condyle are expected to obtain rigid bony fixation after long observation periods. Therefore, short observation periods are needed to detect differences between two different surgical techniques. A canine study using weight-bearing implants was able to detect differences between compaction and drilling when data from 2 and 4 weeks were pooled<sup>33</sup>. Another canine study using non-weight-bearing implants found differences between compaction and drilling at

early observation periods (0, 3 and 6 weeks), but not at 9 weeks<sup>67</sup>. Anchorage of a cementless implant depends on both the reparative response and the mechanical stimulus. The reparative response dominates early after surgery (at 5 weeks), and then diminishes with increasing time after surgery as mechanical stimulus plays a more dominant role<sup>81</sup>.

### Implant characteristics

All implants were manufactured by Biomet, Inc. (Warsaw, Indiana, USA) and consisted of titanium alloy (Ti-6-Al-4V) with a porous coated surface deposited by plasma-spray technique. Surfaces and coatings were manufactured as on commercial available implants.

*Study III.* Implants were cylindrical (height: 10 mm; diameter: 5.6 mm) with a porous coated titanium surface. For the majority of the porous surface, the pore size, as assessed by the manufacturer, was within the 100 to 1000  $\mu\text{m}$  range. The implants were thermal sterilized.

*Study IV.* Implants were cylindrical (height: 10 mm; diameter: 6.0 mm) with a HA plasma sprayed porous coating (thickness 50  $\mu\text{m}$ ). The implants were sterilized by gamma radiation.

The porosity and roughness of the implants, as well as the crystallinity and purity of the HA coating, were not determined.

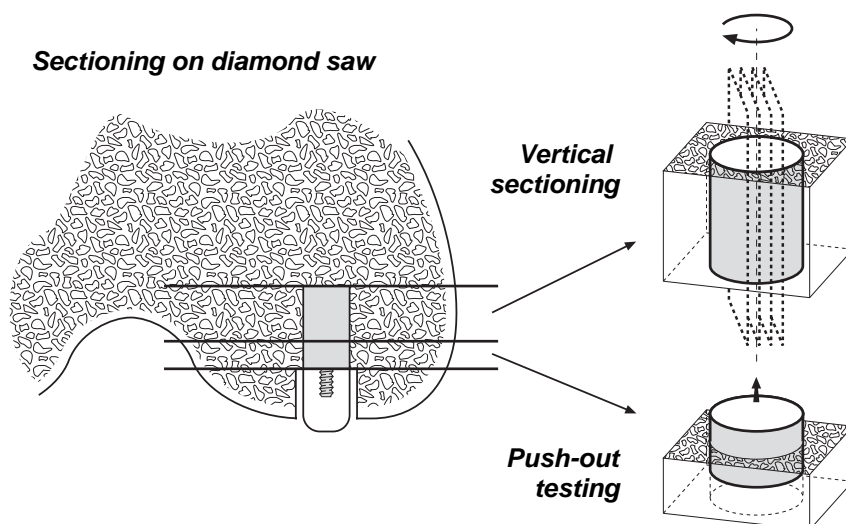
### Postoperative animal care

Postoperative analgesia was provided by injection buprenorphin, and transdermal fentanyl<sup>156</sup>. All dogs were allowed full weight-bearing postoperatively. All dogs walked and supported all four limbs at the third day postoperatively. Animal care was done under identical conditions in individual cages. Out-door activities were allowed daily.

### Preparation of specimens

*Study III and IV.* No clinical signs of infection were noticed when opening the knee joints after euthanization. Two standardized sections orthogonal to the long axis of the implant were cut on a water-cooled diamond band saw (Exakt-Cutting Grinding System, Exakt Apparatebau, Norderstedt, Germany) (Figure 9).

**Figure 9.** Preparation of bone-implant specimens. A water-cooled diamond band saw was used. The first specimen was used for mechanical testing, and was stored at  $-20\text{ }^{\circ}\text{C}$  until testing. The second specimen was used for histological evaluation. It was dehydrated in graded alcohol, and subsequently embedded in methylmetacrylate. Later, the specimen was sectioned using the vertical section method.



Mechanical testing was always performed on the section with the 3.5 mm implant part closest to the joint space, whereas histomorphometry was done on the section with the remaining 6.5 mm of the implant. This selection was chosen to theoretically reduce variance of the estimates; however, in doing so bias might have been introduced if the area of interest does not represent the entire implant. This might explain, why a mismatch between mechanical and histomorphometric parameters previously has been observed in implant research<sup>85;181</sup>, and correlation between mechanical and histomorphometric data should be made with caution. The fixation of implants increases by increasing both the bone in contact with the implant and the connectivity of the cancellous bone. The histomorphometric analysis provides results for the bone implant contact whereas the push-out data may be more sensitive to the extent of the connectivity, and to the orientation of the trabeculae<sup>132</sup>.

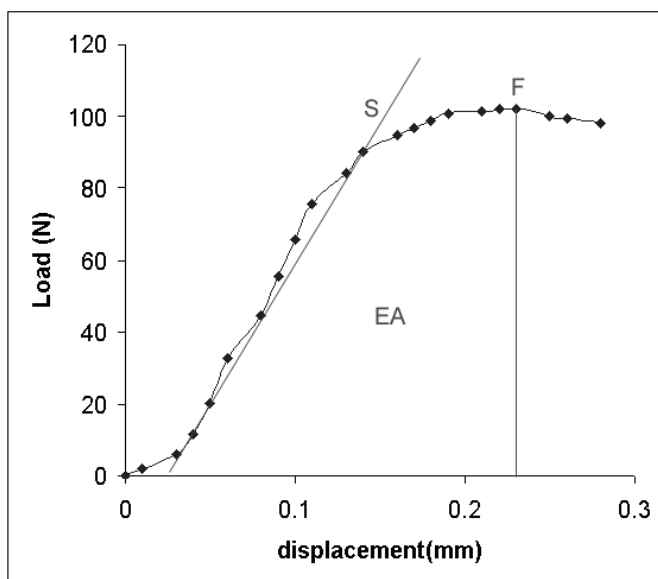
*Study V.* The specimens were cut on a water-cooled diamond band saw (Exakt-Cutting Grinding System, Exakt Apparatebau, Norderstedt, Germany) leaving the 10 mm deep part of the cavities for analysis. Hereby, the analyses in study V were performed on the same location in the lateral femoral condyles as the implants in study III and IV were positioned. Cylindrical specimens (length: 10 mm; diameter: 14 mm), appropriate for micro-CT scanning, with the cavity approximately in the center were harvested using a 14 mm trephine. After completing micro-CT scanning three horizontal sections from the middle part of the specimens were cut for histomorphometry.

### Mechanical testing

The strength of the interface between implant and surrounding tissue can be measured by push-out, pull-out or removal torque test<sup>37;66;67;197</sup>. However, none of these tests mimics the simultaneously bending, shearing and compressive forces that a prosthetic component is subjected to clinically. We chose a push-out test because such a test measures the strength between the implant and the surrounding tissue in the load direction that an implant is mostly subjected to in the patient. At push-out test, the interface strength is a result of a variety of compressive, tensile and shear stresses as the porous-coated implants mechanically interlock with surrounding bone<sup>143</sup>. We tested the implants to failure, and thus the push-out test was destructive making histological analysis of those samples impossible. This could have been eliminated by using non-destructive tests<sup>14</sup>. Additionally, a non-destructive fatigue test might be more clinically relevant, simulating loading below the maximal fixation strength before failure of the interface.

Harrigan et al. have shown that results of push-out tests can only be reasonably compared for implants that are very similar in geometry, and that are loaded in very controlled conditions<sup>73</sup>. In the present studies (III, IV), variation in test conditions was minimized by testing all specimens the same day without changing the setup. In addition the bone-implant specimens within pairs were kept frozen at  $-20\text{ }^{\circ}\text{C}$  for identical time periods before testing. As recommended, the bone-implant specimens to be compared had similar thickness<sup>14</sup>. The mean (SD)

thickness was for Ti implants: 3.2 mm (0.3 mm), and for HA implants: 3.2 mm (0.2 mm). Dhert et al. have showed in a finite element analysis that the clearance of the hole in the support jig is the parameter that influences the push-out data the most<sup>48</sup>. In order to get a uniform interface stress distribution they recommend that the clearance of the hole in the support jig is at least 0.7 mm. This clearance was used for all push-out tests. The push-out test was done with an Instron Universal test machine (Instron Ltd. High Wycombe, U.K.). For all specimens, a push-out direction equal to the *in vivo* load transfer direction was chosen. In order to standardize the test a preload of 2 N was applied to initiate the contact position in all specimens. A displacement rate of 5mm/minute was used, and load displacement curves were obtained on a computer (Figure 10).



**Figure 10.** Load displacement curve obtained during push-out testing of a HA implant from time 0 inserted with drilling. Ultimate shear strength (MPa) was determined from the maximum force (F) applied until failure of the bone implant interface. Apparent shear stiffness (MPa/mm) was obtained from the slope (S) of the straight part of the load displacement curve. Energy absorption ( $J/m^2$ ) was calculated as the area (EA) under the load-displacement curve until failure. All evaluations were done blinded. The most important parameter for implant anchorage seems to be energy absorption which is a function of interfacial strength and stiffness.

It has been postulated that the proper comparison to be used in push-out tests is between failure loads (N), as stress calculations done by dividing the failure load by the interface area are not valid<sup>73</sup>. However, we found it important to take into consideration that the specimens prepared for push-out testing had different lengths. Thus, we normalized all push-out parameters by the area of cylindrical implants (area =  $\pi DL$ , where D is the diameter and L the length of the implant). The area used to normalize push-out parameters represents the area of a smooth cylinder without considering that the tested implants were porous-coated. Thus, the presented push-out parameters are overestimated compared to the true value. However, the push-out parameters can be compared between compaction and drilling within Ti (III) and within HA (IV) implants, respectively.

#### Histological and histomorphometric analysis

Undecalcified blocks embedded in MMA were sectioned for histology on a microtome (KDG-95, MeProTech, Netherlands). The sections were approximately 25-30  $\mu m$  thick with a distance of 400  $\mu m$  (III, IV) or 1300  $\mu m$  (V) between sections. The soft tissue was stained red by 0.4% basic fuchsin during dehydration in graded ethanol (70-100%), and bone was later counterstained with 4% light green<sup>65</sup>. Histologically, discrimination of the different bony tissues was done between non-vital bone, woven bone, and lamellar bone (III). The non-vital bone consisted of small bony chips or larger pieces of bone with cracking of the lamellar structure and loss of osteocytes. Woven bone had random orientation of osteocytes, large osteocytes and random orientation of collagen fibers whereas lamellar bone was arranged in parallel lamellae. In addition, polarized microscopy was applied to reveal the parallel lamellar structure of lamellar bone when difficulties in discriminating between woven and lamellar bone were encountered<sup>28</sup>. Despite thorough examination of the different bony tissues (non-vital, lamellar, and woven bone), the superior fixation with compaction at 4 weeks for Ti implants could not be explained from



histomorphometric parameters (III). Therefore, the time-consuming discrimination of the different bony tissues was not performed for the histomorphometric analyses of HA coated implants in study IV.

Histology was done qualitatively by simple description (III, IV), and quantitatively by histomorphometry (III, IV, V). An Olympus BX 50 microscope modified for stereology was used. The microscopic field is transmitted to a computer monitor by a video camera attached to the microscope. Blinded histomorphometry was performed by use of a stereological software program (CAST-Grid, Olympus Denmark A/S). The software superimposes a user-specified grid or counting frame on the microscopic field captured on the monitor. All histomorphometric analyses were done with objective x 10 and ocular x 10. During evaluation only one focus plane was analyzed. The depth of focus with plain unfiltered light is approximately 3.0 - 3.8  $\mu\text{m}$ . The penetration depth of the light green into bone is 5 - 10  $\mu\text{m}$  after 2 minutes of staining<sup>141</sup>.

### Histological sampling

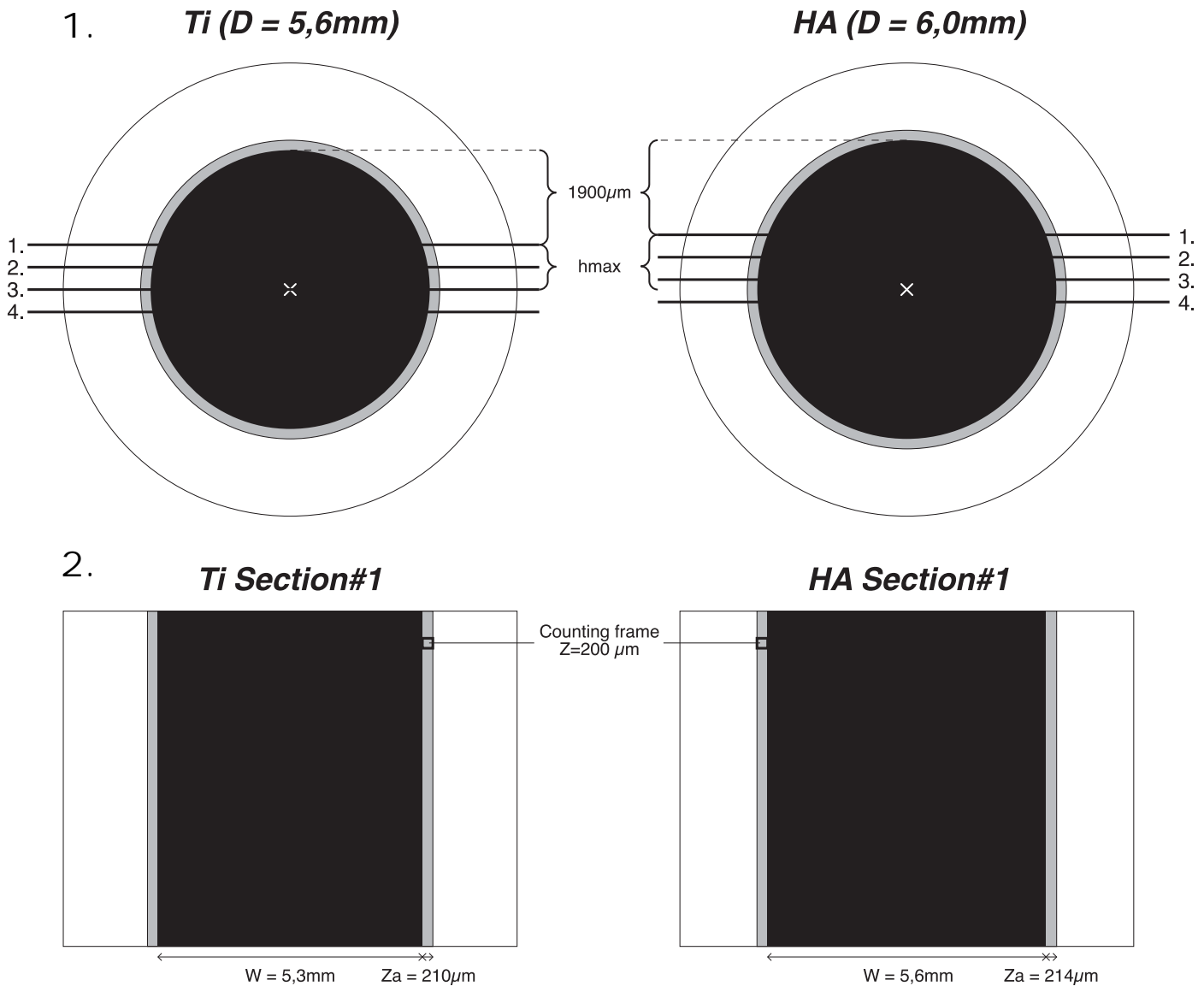
Cancellous bone is anisotropic with respect to morphology and mechanical properties<sup>21;28;61;201;207</sup>. Moreover, when inserting a loaded implant, the surrounding bone will adapt by reorientation of the bone trabeculae<sup>64;199</sup>. As this reorientation might very well differ between different treatment groups, the anisotropy of the cancellous bone must be considered at histomorphometry. When volumes are estimated from two-dimensional sections, the anisotropy raises no problem, but when surfaces are estimated, bias is introduced by the anisotropic orientation of cancellous bone. Bias means that the estimate systematically deviates from the true value, and thus it is very important to eliminate bias. In order to eliminate bias of surface estimates in bone-implant research, Overgaard et al. have introduced the vertical sectioning method<sup>144</sup>. Four requirements must be fulfilled when using the

vertical sectioning method. 1) A vertical axis of the specimen must be defined. It seems natural to choose the long axis of the implant when cylindrical implants are used. 2) The specimen must be rotated randomly around the vertical axis before sectioning. 3) Serial cut random positioned sections must be performed parallel with the vertical axis. 4) The vertical axis must be identified in each section, and a set of isotropic uniform random (IUR) test lines is applied in the microscopic field of vision. The IUR test lines are given by a weight proportional to the sine of the angle between the test line and the vertical axis. Hereby stereological methods are applied to obtain quantitative information about three-dimensional structures from observations made on two-dimensional sections<sup>70</sup>.

The vertical section method was used in study III and IV for obtaining unbiased estimates of bone implant contact. However, bias might have been introduced when also using the vertical sections to obtain estimates of volume densities in a 200  $\mu\text{m}$  peri-implant zone (Figure 11). Volume density in this zone was counted by applying a counting frame with a length of 200  $\mu\text{m}$  from the implant surface on every section. However, only in the one section being cut in perpendicular to the implant surface the length of the counting frame will equal the 200  $\mu\text{m}$  peri-implant zone. In all other sections, the length of the counting frame will be too short to represent the entire 200  $\mu\text{m}$  peri-implant zone. The farther away from the center section this counting frame is applied the greater the discrepancy between the peri-implant zone of interest and the actual counted zone will become. The actual length that a counting frame must have to represent the entire width of the peri-implant zone of interest in the actual section ( $z_a$ ) can be calculated from the formula:

$$z_a = ((\frac{1}{2}D+z)^2 - (x)^2)^{\frac{1}{2}} - ((\frac{1}{2}D)^2 - x^2)^{\frac{1}{2}},$$

where  $z$  = width of peri-implant zone of interest,  $D$  = diameter of implant,  $x$  = distance the section is cut from the center of the implant.



**Figure 11.** Effect of section level on peri-implant zone of interest.

1. After initial random rotation around the vertical axis, the first cut is made approximately 1900  $\mu\text{m}$  from the surface of the implant. The distance between each cut is 450  $\mu\text{m}$  (25  $\mu\text{m}$  section + 425  $\mu\text{m}$  loss due to saw blade). Thereby, the maximum distance ( $h_{\text{max}}$ ) from the outermost section to the center of the implant is 900  $\mu\text{m}$  for Ti implant with diameter (D) of 5.6 mm, and 1100  $\mu\text{m}$  for HA implant with diameter (D) of 6.0 mm.

2. Outermost section. The shown width ( $w$ ) of the implant in the outermost section can be calculated as:  $w = 2((D/2)^2 - (h_{\text{max}})^2)^{1/2}$ . The width of the peri-implant zone of interest in the actual section ( $z_a$ ) can be calculated as:  $z_a = ((1/2D+z)^2 - (h_{\text{max}})^2)^{1/2} - 1/2w$ , where  $z$  is the width of the peri-implant zone of interest. The applied counting frame of 200  $\mu\text{m}$  covers the inner 95 % (for Ti implants) and 93 % (for HA implants) of the peri-implant zone of interest.

In order to reduce bias of bone volume density in study III and IV, only four serially cut sections in the central part of the implants were used. With the applied cutting procedure, the applied counting frame of 200  $\mu\text{m}$  covers at least the inner 93 % of the peri-implant zone of interest (Figure 11). This bias was accepted, and thus the counting frame was not adjusted in length for each section (III, IV). In study V, where bone surface was not estimated, bone volume densities were determined from horizontal sections to avoid bias.

Sampling was applied to improve efficiency, which means that the estimate is obtained with a low variability after spending a moderate amount of time. Overgaard et al. evaluated the variances from different sampling levels in a human implant study, and found that the major contribution to the total variance was the biological variation between humans, whereas variance from section and field of view only contributed to a minor degree<sup>144</sup>. Thus, the workload could be reduced by analyzing only 3-4 sections per implant without affecting the total variance greatly. Theoretically, the use of inbred dogs should reduce the biological variance compared with humans. However, the biological variance in our studies probably still is relative large. Hence, 3 sections per implant were analyzed in study V, and 4 sections per implant in study III and IV.

#### **Tissue implant contact and tissue volume density**

Linear intercept technique was applied to estimate tissue implant contact. Sine-weighted straight test lines were superimposed on the microscopic field, and when the IUR lines cut the implant surface, the type of tissue in contact with the implant was registered. Point counting was applied to estimate tissue volume density. A counting frame with random positioned points was superimposed on the microscopic field, and the type of tissue hit by point was registered. For both the linear intercept technique and point counting, the probes were applied so approximately 100 events (n) of interest were counted per implant. Given that enough sections are sampled, the contribution to the total variance from fields of view will hereby be approximately 10% ( $CV=1/\sqrt{n}$ )<sup>70</sup>.

#### **Micro-CT scanning**

In study V, the diameters of the prepared cavities were determined from micro-CT scanning ( $\mu\text{-CT}$  20, Scanco Medical AG, Zürich, Switzerland) mainly for practical reasons. The specimens were scanned in high-resolution mode, with an x-, y-, and z-resolution around 20  $\mu\text{m}$ . A detailed description of the system has been published by Rueggsegger et al.<sup>157</sup>. The procedure for scanning each specimen involved a scout view (a two-dimensional side preview of the entire specimen), selection of the area for scanning, scanning, and analysis. A 3 mm long and 14 mm diameter cylindrical section centered around the center of each specimen was scanned and analyzed. Each section contained 200 micro-tomographic slices with a slice thickness of 15  $\mu\text{m}$ . For each specimen, 3 random micro-CT slice images with a distance of 75  $\mu\text{m}$  between were used for 2-D evaluation of the prepared holes. By use of the software, we were able to draw the circumference of the cavity in a horizontal 2-D view, and the area as well as the length (longest chord) of the outlined cavity was automatically calculated. From these measurements the roundness of the holes were calculated as: Roundness =  $(4 \times \text{Area}) / (\pi \times \text{Length}^2)$ <sup>158</sup>. The median roundness (interquartile range) was 0.96 (0.95 – 0.98) for compacted specimens, and 0.99 (0.98 – 0.99) for drilled specimens (Table 10). Thus, the holes resembled a circle as a perfect circle has a roundness of 1.0, and the measured areas of the holes therefore were converted to equivalent circular diameters ( $D_{\text{Circ}}$ ) by using the formula:  $D_{\text{Circ}} = (4 \times \text{Area} / \pi)^{1/2}$ <sup>158</sup>. The specimens were kept frozen until micro-CT scanning. As the median (interquartile range) equivalent circular diameter of the control cavities prepared by 5.6 mm drilling were 5.6 mm (5.6 – 5.6 mm), the storage conditions did not seem to influence the diameter of the holes.

#### **Reproducibility**

Reproducibility (intra-observer) variation was calculated from double measurements performed by the same person on identical equipment, and was calculated as coefficient of variation (CV) by the method described by Therkelsen<sup>190</sup>:

$$s^2 = (1/2k) \sum d^2,$$

where  $k$  is the number of double measurements and  $d$  is the difference between first and second assessment. Then CV is calculated as:

$$CV = s/x,$$

where  $x$  is the mean value of first and second assessment.

The double measurements were short-term as they were done within one month.

*DEXA scanning.* To determine reproducibility for the scanning procedure, for one femur the instrument from the postoperative DEXA scan was superimposed onto eight consecutive preoperative DEXA scans of the same femur. From this the CV was calculated to 0.05% for Gruen Zone 7B, and 0.05% for Gruen Zone 7C.

*Push-out test.* Double measurements were done on eight randomly selected load displacement curves normalized by surface area. The CV for ultimate shear strength, apparent shear stiffness, and energy absorption were 0%, 2%, and 0%, respectively. The low coefficients of variation for ultimate shear strength and energy absorption is due to the computer's automatic identification of the maximum force and calculation of the area under the curve until the maximum force is reached. In contrast, the greater CV for apparent shear stiffness is due to the individual judgments of the slope of the straight part of the load displacement curve (Figure 10).

*Histomorphometry.* Double measurements were done for tissue implant contact on 8 randomly selected Ti implants. The CV for total bone, non-vital bone, lamellar bone, woven bone, fibrous tissue and marrow were 6%, 16%, 12%, 20%, 10%, and 4%, respectively.

*Micro-CT.* The CV, determined from double-measurements on all 14 scanned specimens, was 0% for the equivalent circle diameter, and 0.1% for the roundness.

## Statistics

McNemar's test was used to test differences between binominal paired data (I and II).

For continuous paired data probability plots of the differences were done. When probability plots showed differences between pairs to be distributed normally, a paired  $t$  test was applied (I and II). When the probability plot showed that the differences between pairs were not distributed normally the Wilcoxon signed-rank test was applied (I, III-V). Differences in fracture forces between femurs that had smooth tamps and femurs that had toothed broaches were assumed to be distributed normally and a paired  $t$  test was applied (I). Two-sided  $p$ -values less than 0.05 were considered significant.

Normally distributed data are presented as means with standard deviations whereas data that are not normally distributed are presented as medians with inter-quartile ranges.

## Results

### Femoral fracture (I, II)

**Femoral fracture rates.** When the proximal femur was prepared with bulky AP instrumentation developed for cemented THR, significantly more fractures had occurred at preoperative templated size with the single pass smooth tamping technique compared with the single pass broaching technique (Table 2) (I). When slim AP instrumentation for cementless THR was used, there was no statistically significant difference in femoral fracture rates between compaction and rasping (Table 2) (II). However, femoral fractures only occurred in the compaction group, and at maximum test conditions, five of 10 femurs had fractured in the compaction group (II).

**Femoral fracture location.** Some femurs fractured at more than one location when bulky AP instrumentation was used (I). The fracture pattern was identical for the broached and tamped femurs, with 2/3 of the fractures located in the calcar region and 1/3 of the fractures at the greater trochanter. For the femurs that had broaches, fractures were localized only to the most proximal part, whereas the femurs that had tamps had more severe fractures propagating distally (Figure 12). In contrast all fractures that occurred with compaction, when slim AP instrumentation was used, were lateral longitudinal fissures through the proximal part of the greater trochanter (Figure 13) (II).

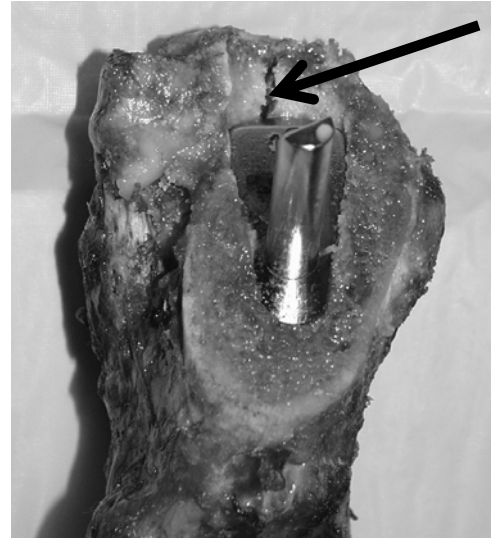
**TABLE 2.** Accumulated numbers of femoral fractures at increasing instrument sizes (I, II). a: significantly different compared with broaching (p=0.04). b: significantly different compared with broaching (p=0.02).

Surgical technique		Accumulated numbers of femurs that had fractured at			
		One size below preoperative templated size	Preoperative templated size	One size above preoperative templated size	Two sizes above preoperative templated size
Study I (cemented, bulky AP instruments)	Tamping (n = 10)	3	8 <sup>a</sup>	9 <sup>b</sup>	-
	Broaching (n = 10)	0	2	2	-
Study II (cementless, slim AP instruments)	Compaction (n = 10)	1	2	2	5
	Rasping (n = 10)	0	0	0	0



**Figure 12.**

A femoral fracture that occurred with a bulky AP smooth tamp from study I. The fracture initiated at the calcar region before propagating distally. The fracture occurred before reaching preoperative templated size.



**Figure 13.**

A longitudinal fissure (arrow) in the greater trochanter that occurred with a slim AP smooth tamp in study II.

*Force needed for fracture to occur (I).* In the two isolated pairs where the femurs with broaches fractured, the corresponding femurs with tamps fractured at the identical instrument size. For both pairs, the fractures occurred at the preoperative templated size. Because femurs with tamps and femurs with broaches fractured at the identical instrument sizes, the overall forces needed to fracture the femurs could be compared. The mean overall force (SD) applied to the femur before fracture occurred was 0.5 (0.1) MN for the femurs

that had smooth tamps compared with 1.9 (0.1) MN for the femurs that had toothed broaches ( $p = 0.01$ ). Thus, significantly less applied work (less overall force) was needed to induce a fracture with tamping than with broaching.

*Force applied at fracture compared with the initial applied force.* Both for bulky and slim AP tamps, a significantly greater force was applied at fracture compared with the initial applied force (Table 3) (I, II).

**TABLE 3.**

*Smooth tamps: Force applied at fracture compared with initial applied force (I, II). a: significantly different compared with initial applied force ( $p = 0.01$ ).*

Surgical technique	Mean (SD) applied forces for the instrument sizes at which fracture occurred	
	Initial force (N)	Force at fracture (N)
Study I, bulky AP smooth tamps (n = 9)	3690 (265)	5591 (1886) <sup>a</sup>
Study II, slim AP smooth tamps (n = 5)	3559 (326)	6248 (1524) <sup>a</sup>

### BMD evaluated by DEXA (I)

One of the femurs that fractured at the appropriate clinical end-size tamp had a severe fracture before the tamp was seated fully. Therefore, the postoperative DEXA scan could not be compared with the preoperative DEXA scan. This femur and the corresponding femur that had a broach were excluded from the DEXA scan analysis. For Gruen Zones 7B (Table 4) and 7C (Table 5) neither tamping nor broaching led to significant changes in postoperative BMD compared with preoperatively BMD. No difference was found between tamping and broaching on the changes in BMD for Gruen Zone 7B and Gruen Zone 7C.

### Compaction versus drilling in canines (III-V)

#### Excluded animals

In one dog from the 4 weeks observation period, a Ti implant was misplaced due to intra-operative breakage of a drill. Thereby, the weight-bearing conditions for both the Ti and HA implants might have been altered in that knee, and hence all

implants from this animal were excluded for analysis<sup>2</sup>.

#### Mechanical implant fixation (III, IV)

Push-out data are presented in table 6.

*Time 0.* Compaction significantly increased ultimate shear strength and energy absorption compared with drilling for both Ti implants inserted with exact-fit and for HA implants inserted press-fit. For Ti implants compaction increased ultimate shear strength by 433 %, and energy absorption by 200% compared with drilling. For HA implants compaction increased ultimate shear strength by 140%, and energy absorption by 300 % compared with drilling. No significant differences in apparent shear stiffness existed between compaction and drilling for neither Ti nor HA implants.

*Time 2 weeks.* For HA implants, compaction significantly increased ultimate shear strength by 32 %, and nearly significantly ( $p=0.06$ ) increased energy absorption by 83% compared with drilling. No significant differences were found between compaction and drilling for any push-out parameter of the Ti implants or for the apparent shear stiffness of the HA implants.

**TABLE 4.**

*Bone mineral density ( $g/cm^2$ ) for Gruen zone 7B.*  
N = 9 pairs of femurs.

BMD for Gruen zone 7B	Tamping	Broaching	Difference (Broaching – tamping)
Preoperative	1.10 (0.22)	1.19 (0.25)	-
Postoperative	1.14 (0.22)	1.16 (0.24)	-
Difference (Postoperative – preoperative)	0.03 (0.08)	-0.03 (0.05)	-0.06 (0.11)

**TABLE 5.**

*Bone mineral density ( $g/cm^2$ ) for Gruen zone 7C.*  
N = 9 pairs of femurs.

BMD for Gruen zone 7C	Tamping	Broaching	Difference (Broaching – tamping)
Preoperative	1.55 (0.31)	1.52 (0.33)	-
Postoperative	1.55 (0.32)	1.51 (0.34)	-
Difference (Postoperative – preoperative)	0.0 (0.06)	-0.01 (0.04)	-0.01 (0.06)

**Table 6.** Push-out parameters for study III and IV. Median values with interquartile ranges of ultimate shear strength, energy absorption, and apparent shear stiffness. a: Significantly different compared with drilling ( $p=0.02$ ). b: Significant differently compared with drilling ( $p=0.03$ ).

Push-out parameter	Implant type	0 weeks (n=8 for Ti; n=7 for HA)		2 weeks (n=8)		4 weeks (n=7)	
		Compaction	Drilling	Compaction	Drilling	Compaction	Drilling
Ultimate Shear Strength (MPa)	Ti, exact-fit (III)	1.6 (0.8-2.0) <sup>a</sup>	0.3 (0.1-0.6)	4.0 (2.3-5.7)	4.6 (3.2-5.5)	6.0 (5.8-6.7) <sup>a</sup>	5.0 (3.6-5.8)
	HA, press-fit (IV)	2.4 (1.8-3.0) <sup>a</sup>	1.0 (0.8-1.5)	5.0 (4.7-5.4) <sup>a</sup>	3.8 (3.5-4.2)	5.6 (5.4-7.0)	5.9 (4.6-6.8)
Energy Absorption (kJ/m <sup>2</sup> )	Ti, exact-fit (III)	0.3 (0.1-0.5) <sup>a</sup>	0.1 (0.0-0.1)	0.6 (0.3-1.2)	0.6 (0.3-0.9)	1.2 (1.0-1.5) <sup>a</sup>	0.8 (0.8-1.0)
	HA, press-fit (IV)	0.4 (0.3-0.5) <sup>b</sup>	0.1 (0.1-0.2)	1.1 (0.9-1.3)	0.6 (0.4-1.1)	1.1 (1.0-1.4)	1.3 (0.9-1.7)
Apparent Shear Stiffness (MPa/mm)	Ti, exact-fit (III)	6 (3-11)	0 (0-5)	16 (11-22)	23 (17-29)	25 (18-34)	24 (17-27)
	HA, press-fit (IV)	21 (9-26)	10 (4-13)	17 (12-25)	15 (13-29)	20 (17-24)	21 (14-31)

*Time 4 weeks.* For Ti implants, compaction significantly increased ultimate shear strength by 20 % and energy absorption by 50 % compared with drilling. No significant differences were found between compaction and drilling for any push-out parameter of the HA implants or for the apparent shear stiffness of the Ti implants.

*Comparison between 0, 2, and 4 weeks.* For Ti implants inserted either with compaction or drilling, and for HA implants inserted with drilling, the median values of ultimate shear strength and energy absorption increased with the time of *in vivo* implantation. However, for HA implants inserted with compaction, the median value of energy absorption reached maximum already after 2 weeks.

#### Morphology of peri-implant tissue (III, IV)

*Time 0.* In all specimens the peri-implant tissue consisted of a mixture of small chips of fragmented bone, distorted lamellar bone, regular lamellar bone, bone marrow, and empty spaces. No woven bone or fibrous tissue was present at time 0. For both the Ti implants inserted with exact-fit (Figure 14 and 15) and for HA implants inserted with press-fit (Figure 16 and 17) the compacted specimens had more distorted bone in the interface compared with drilled specimens; however, this difference in morphology was most pronounced for the HA implants inserted with press-fit (Figure 16 and 17).

Page 41:

Figure 14 and 15 show histological sections from the same dog.

**Figure 14.** Histological section of a compacted specimen with a Ti implant inserted exact-fit at 0 weeks stained with light green and basic fuchsin. Bone is green and soft tissue is red. Note the higher presence of distorted lamellar bone in the interface compared with figure 15. Plain light-microscopy, x 40.

**Figure 15.** Histological section of a drilled specimen with a Ti implant inserted exact-fit at 0 weeks. Note the chips of fragmented bone in the interface. Plain light-microscopy, x 40.

Figure 16 and 17 show histological sections from the same dog.

**Figure 16.** Histological section of a compacted specimen with a HA implant inserted press-fit at 0 weeks. Note the higher presence of distorted lamellar bone in the interface compared with figure 17. Plain light-microscopy, x 40.

**Figure 17.** Histological section of a drilled specimen with a HA implant inserted press-fit at 0 weeks. Plain light-microscopy, x 40.



Figure 14

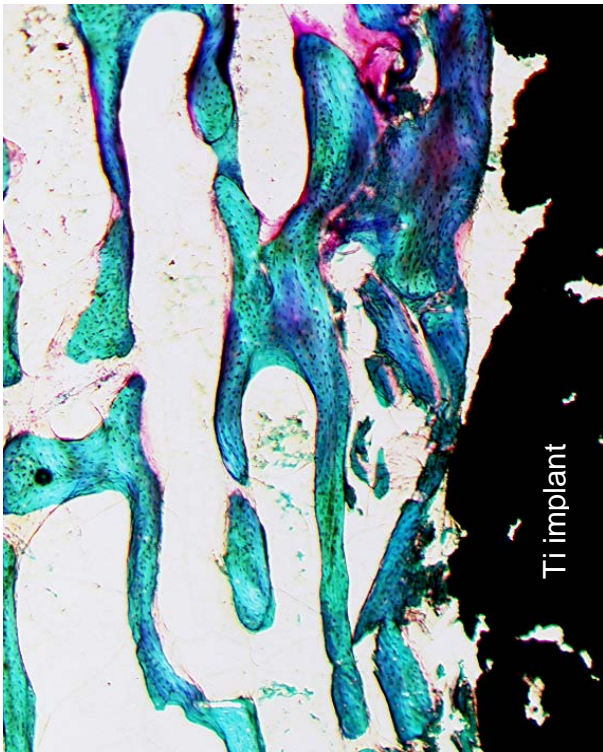


Figure 15

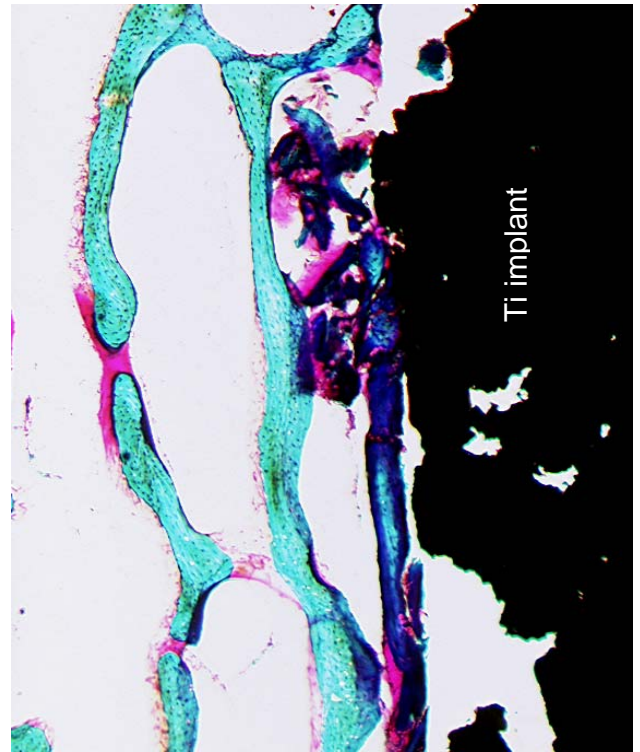


Figure 16

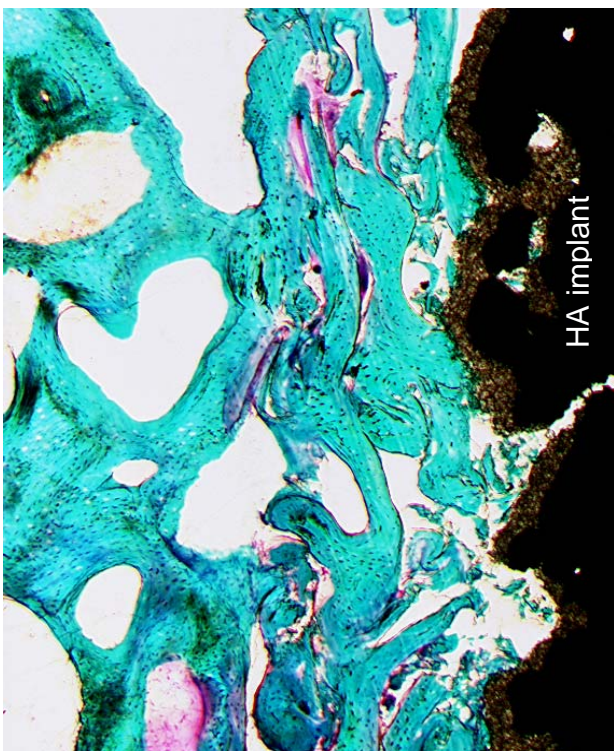
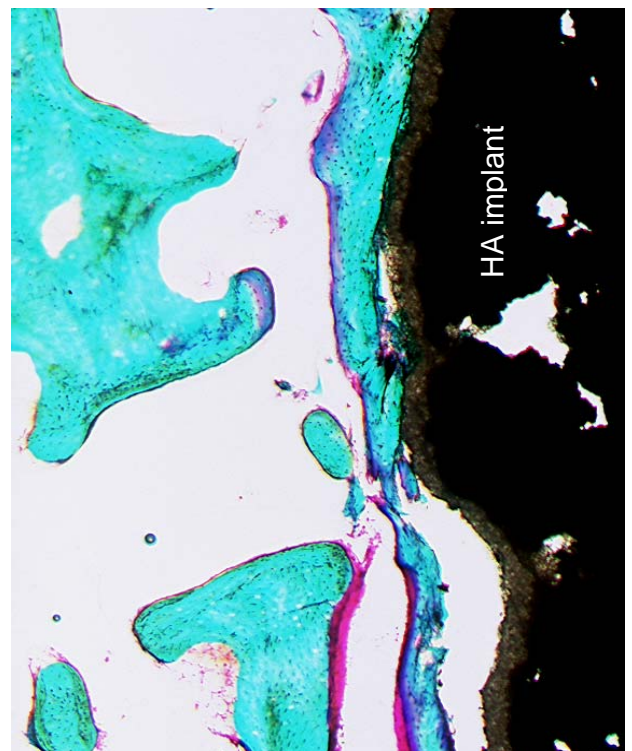


Figure 17



Page 43:

Figure 18, 19, 20, and 21 show histological sections from the same dog.

**Figure 18.** *Histological section of a compacted specimen with a Ti implant at 2 weeks.* Note the non-vital bone and resorptive lacunae (arrow). Plain light-microscopy, x 100.

**Figure 19.** *Histological section of a drilled specimen with a Ti implant at 2 weeks.* Note the vital woven bone formed on top of the lamellar bone. Plain light-microscopy, x 100.

**Figure 20.** *Histological section of a compacted specimen with a HA implant at 2 weeks.* Note the non-vital and vital compressed lamellar bone. Plain light-microscopy, x 100.

**Figure 21.** *Histological section of a drilled specimen with a HA implant at 2 weeks.* Note the non-vital and vital compressed lamellar bone as well as the lack of HA coating (arrow). Plain light-microscopy, x 100.

2 weeks. In all specimens the peri-implant tissue consisted of a mixture of non-vital bone, woven bone, lamellar bone and bone marrow. No fibrous membranes were found in any of the specimens. For Ti implants inserted with exact-fit, the compacted specimens had a high presence of non-vital bone in the bone implant interface. This non-vital bone consisted of small bony chips or larger pieces of bone. A high resorptive activity with resorptive lacunae into the surfaces of the non-vital bone was found (Figure 18). For Ti implants inserted exact-fit with drilling (Figure 19), the bony tissues found in the interface mainly consisted of vital bone, and the impression was that less resorptive activity existed compared with compacted specimens. For HA implants inserted with press-fit, the morphology of the peri-implant tissue did not differ between compacted and drilled specimens. The bony tissue mainly consisted of non-vital and compressed vital lamellar bone (Figure 20 and 21).

4 weeks. For Ti implants the bone in the interface at 4 weeks mainly consisted of vital bone for both drilled and compacted specimens. At 4 weeks there

was no impression of a difference in resorptive surfaces between compacted and drilled specimens for Ti implants. For Ti implants inserted with exact-fit, two of seven drilled specimens were partially surrounded by a fibrous membrane (Figure 22 and 23) compared with no fibrous membranes in compacted specimens. For HA implants inserted with press-fit no fibrous membranes were present, and the morphology of the peri-implant tissue did not differ between compacted and drilled specimens. The bony tissue mainly consisted of non-vital and compressed lamellar bone around HA implants for both compacted and drilled specimens (Figure 24 and 25).

*Qualitative assessment of lack of HA coating.* HA coating was only missing in very few areas of the implants (Figure 21), and coating delamination was not present. The maximum length of an implant surface not covered by HA coating was 200  $\mu\text{m}$ . No difference in lack of HA coating was observed between different surgical techniques (compaction and drilling), or between different observation periods (0, 2, and 4 weeks).



Figure 18

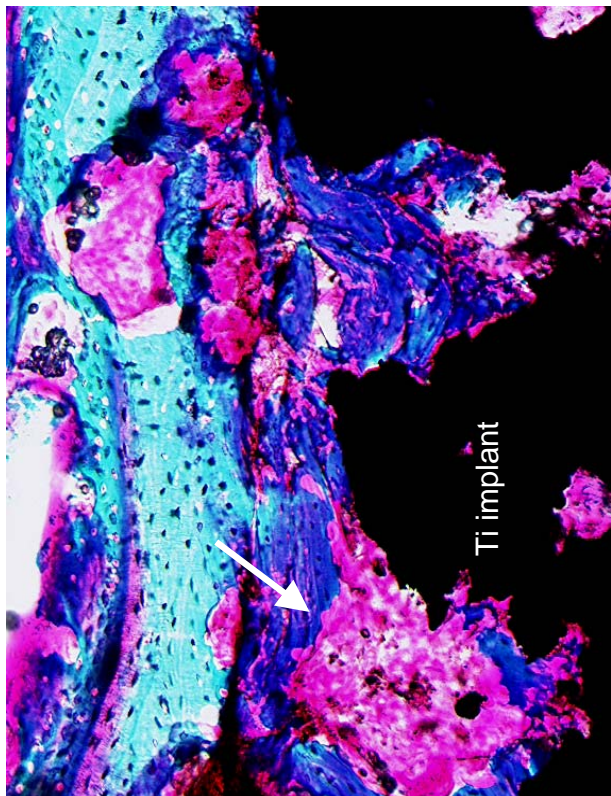


Figure 19

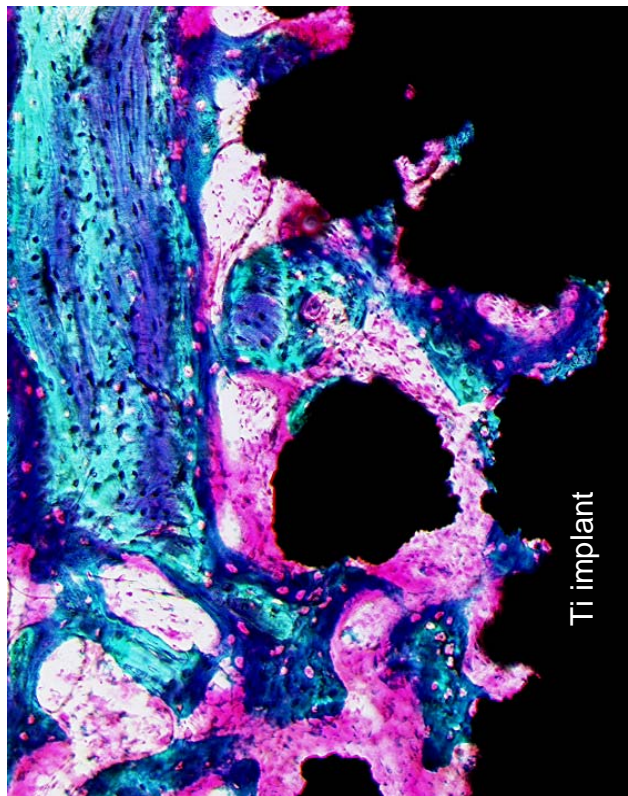
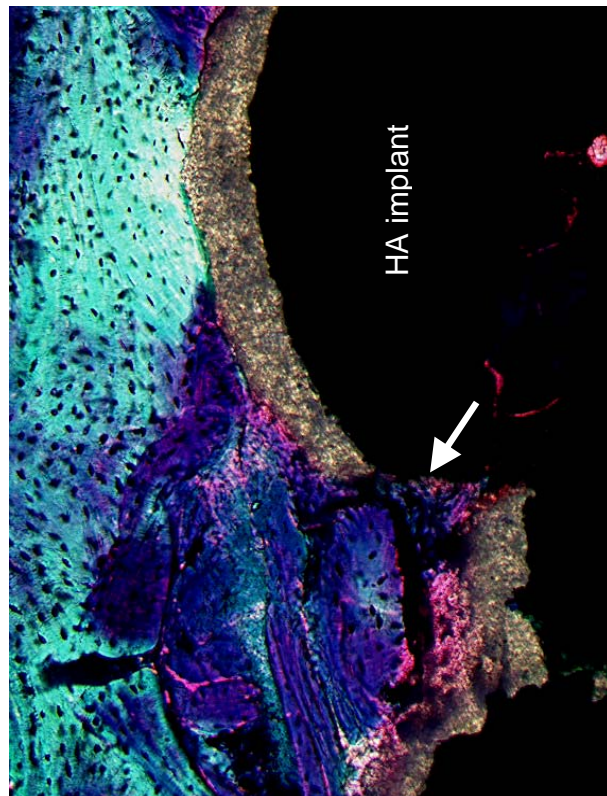


Figure 20

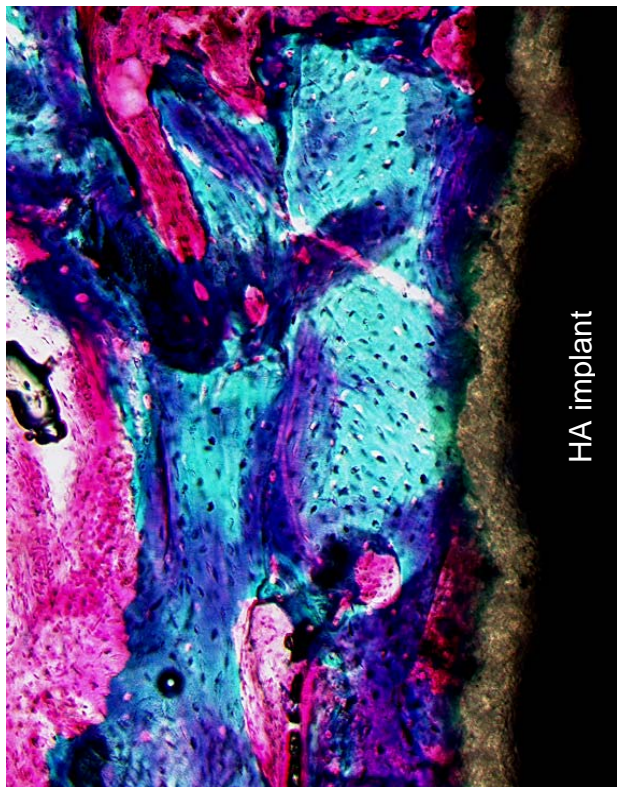

Figure 21



Page 45:

**Figure 22.** Histological section of a drilled specimen with a fibrous membrane surrounding a Ti implant at 4 weeks. The superimposed frame shows the location of figure 23. Plain light-microscopy, x 40.

**Figure 23.** High magnification of the fibrous membrane from figure 22. Plain light-microscopy, x 100.

**Figure 24.** Histological section of a compacted specimen with a HA implant at 4 weeks having a high bone implant contact. The superimposed frame shows the location of figure 25. Plain light-microscopy, x 40.

**Figure 25.** High magnification of area from figure 24. Note the compressed lamellar bone in contact with the implant. Plain light-microscopy, x 100.

### Tissue implant contact (III, IV)

*Compaction versus drilling.* At all observation periods, higher median values of bone implant contact were found in compacted specimens compared with the paired drilled specimens; however, only for Ti implants at 0 and 2 weeks, and for HA implants at 0 weeks, the differences between compaction and drilling were statistically significant (Table 7). Further analysis revealed that the more bone in contact with Ti implants in

compacted specimens at 2 weeks was a result of more bone being present from the time of surgery. Thus, significantly more non-vital bone and lamellar bone were in contact with Ti implants in compacted specimens at 2 weeks compared with drilled specimens. In contrast, no difference in de novo formed woven bone in contact with Ti implants was found between compacted and drilled specimens at 2 weeks (Table 8).

**Table 7.** Bone implant contact (%) for study III and IV. Median values (interquartile ranges) of total bone in contact with the implant.

Bone implant contact (%)	0 weeks (n=8 for Ti, and n=7 for HA)		2 weeks (n=8)		4 weeks (n=7)	
	Compaction	Drilling	Compaction	Drilling	Compaction	Drilling
Ti implants inserted with exact-fit (III)	27 (24-27) <sup>a</sup>	5 (3-13)	35 (28-38) <sup>a</sup>	20 (16-22)	34 (26-38)	31 (17-40)
HA implants inserted with press-fit (IV)	42 (40-45) <sup>b</sup>	29 (25-31)	40 (34-48)	36 (30-48)	45 (44-52)	42 (41-49)

a: Significantly different compared with drilling ( $p=0.01$ )

b: Significantly different compared with drilling ( $p=0.02$ )

**Table 8.** Tissue implant contact (%) for Ti implants inserted with exact-fit (III). Median values (interquartile ranges) of non-vital bone, lamellar bone, woven bone, and fibrous tissue in contact with the implant.

Tissue implant contact (%)	2 weeks (n=8)		4 weeks (n=7)	
	Compaction	Drilling	Compaction	Drilling
Non-vital bone	17 (14-25) <sup>a</sup>	2 (0-11)	13 (4-26)	9 (4-10)
Lamellar bone	4 (2-8) <sup>a</sup>	1 (0-3)	7 (4-8)	8 (6-10)
Woven bone	9 (7-14)	15 (4-17)	13 (2-18)	10 (5-18)
Fibrous tissue	0 (0-0)	0 (0-0)	0 (0-0)	0 (0-32)

a: Significantly different compared with drilling ( $p=0.02$ )



Figure 22

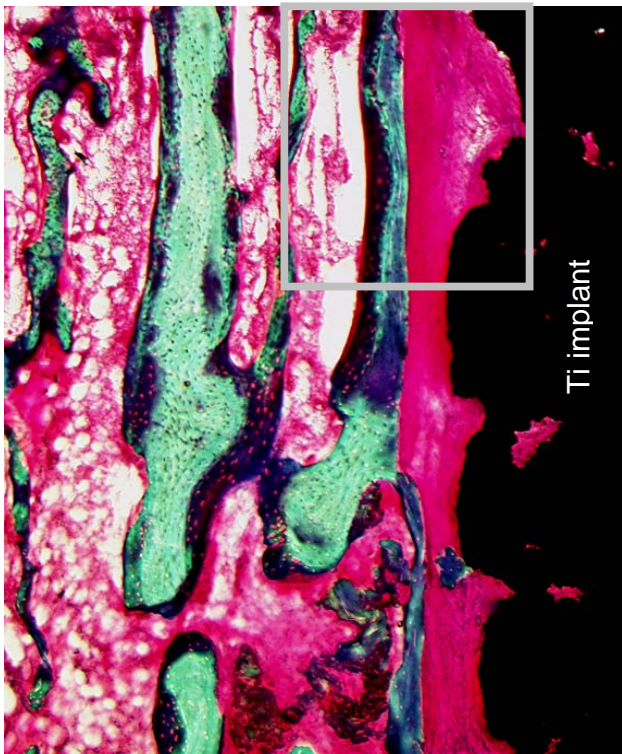


Figure 23

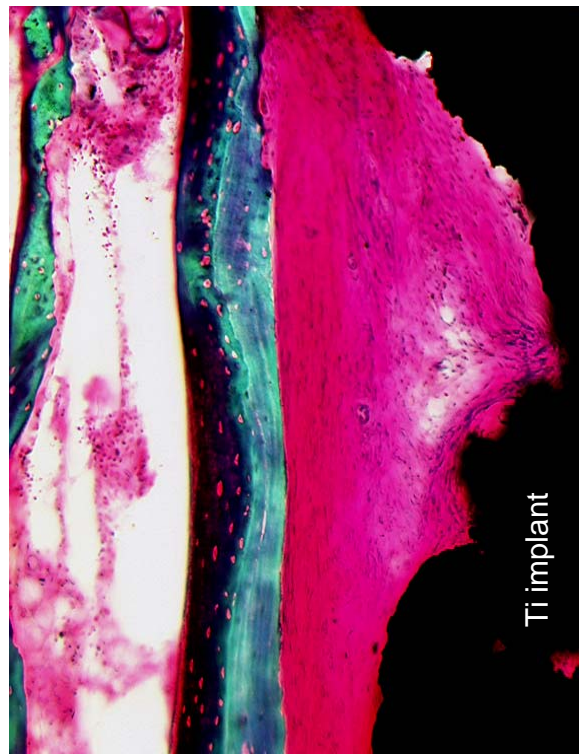


Figure 24

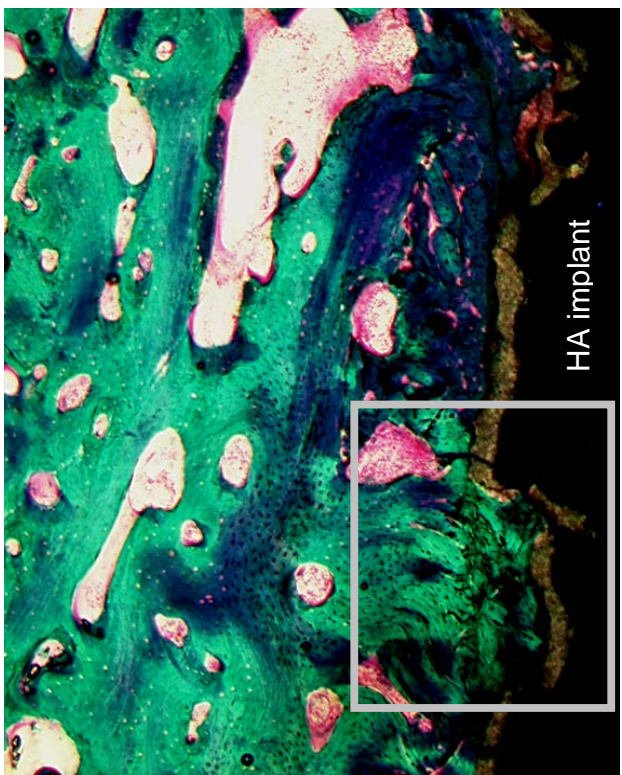
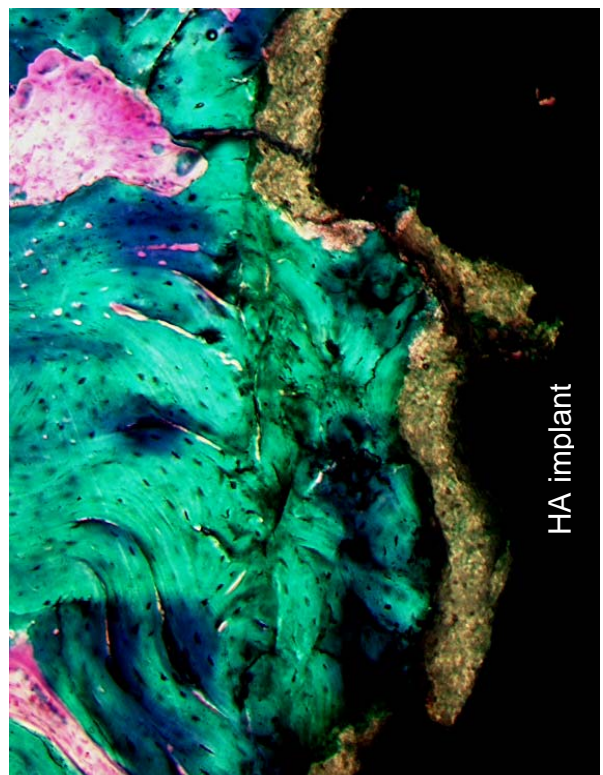


Figure 25



**Table 9.** Peri-implant bone density (%) for study III and IV. Median values (interquartile ranges) of bone densities in a 200 µm peri-implant zone.

Peri-implant bone density (%)	0 weeks (n=8 for Ti; n=7 for HA)		2 weeks (n=8)		4 weeks (n=7)	
	Compaction	Drilling	Compaction	Drilling	Compaction	Drilling
<b>Ti implants inserted with exact-fit (III)</b>	46 (40-48) <sup>a</sup>	23 (11-36)	46 (44-54) <sup>a</sup>	37 (30-39)	47 (44-54)	52 (35-54)
<b>HA implants inserted with press-fit (IV)</b>	52 (51-56)	49 (37-56)	51 (41-61)	45 (41-50)	61 (51-64)	56 (52-69)

a: Significantly different compared with drilling (p=0.02)

### Peri-implant bone density (III, IV)

*Compaction versus drilling.* For Ti implants at 4 weeks, drilling resulted in higher median value of peri-implant bone density compared with compaction; for all other observation periods the median values of peri-implant bone density were higher for compacted than for drilled specimens. However, only for Ti implants at 0 and 2 weeks, the differences between compaction and drilling were statistically significant (Table 9).

### Spring-back (V)

*Peri-cavity bone density.* The median value (interquartile range) of bone density for all specimens in a 2 mm zone adjacent to the prepared cavities was 0.29 (0.24 – 0.35).

### Equivalent circle diameter of prepared cavities.

Compacted cavities had significantly smaller equivalent circle diameters than drilled cavities (Table 10). For drilled cavities, the median value of the equivalent circle diameter equaled the 5.6 mm diameter of the originally prepared cavities. For compacted cavities the median value of the equivalent circle diameter was 91 % of the original 5.6 mm compacted cavities, and 102 % of the initial 5.0 mm pilot drill holes.

*Roundness of prepared cavities.* For both compacted and drilled specimens, the median values of roundness approximated 1.0 (Table 10). However, compacted cavities were significantly less round than drilled cavities.

**Table 10.** Equivalent circle diameter and roundness of prepared cavities (V). Median values with interquartile ranges are presented. N = 7 pairs.

Surgical technique	Equivalent circle diameter (mm)	Roundness
<b>Compaction</b>	5.1 (5.1 – 5.2) <sup>a</sup>	0.96 (0.95 – 0.98) <sup>a</sup>
<b>Drilling</b>	5.6 (5.6 – 5.6)	0.99 (0.98 – 0.99)

a: Significantly different compared with drilling (p=0.02)

**Discussion**

**Femoral fracture (I, II)**

Table 11 presents risk factors of femoral fracture in THR. The present studies add further evidence to the findings that femoral fracture rates in THR are influenced by the surgical technique.

In study I, significantly more fractures occurred with smooth tamps than compared with toothed broaches. Additionally, tamping caused more severe fractures, and less applied work (less overall force) was needed to induce a fracture with tamping than with broaching. For a given impact force, the smooth surfaced tamp advanced in greater increments than the broach, which on the contrary was prevented from advancing by catching its cutting teeth on bone. Thereby the tamp might have induced more sudden and larger increments in hoop-stresses to the femur than the broach, which might be responsible for the increased risk of femoral fracture with smooth tamps.

In accordance with general recommendations for THR, a slightly posterior entrance into the medullary canal was used. Because of the bulky AP instrument shape and the entrance location, the instruments advanced in close contact to cortical bone posteriorly. Fractures often propagated from this posterior area. It appeared that the broach's teeth were able to slice thin layers of the posterior cortical bone, whereas the smooth tamp was not. The hoop-stresses generated in the posterior femoral region might then have been less for broaching than for tamping. To reduce the risk of femoral fracture in THR, Jasty et al.<sup>87</sup> recommend the use of sharp instruments that rapidly clear bone from the cutting teeth.

In study II, femoral fractures occurred only in the compaction group. However, the difference in fracture rates between compaction and rasping was not statistically significant when comparing binominal data in this small sample of 10 pairs of

**Table 11.**

*Risk factors for intra-operative femoral fracture in THR* <sup>12;20;25;31;36;56-58;71;86;91;96;101;106;121;127;129;130;139;147;168;170;183;188;193;195;(I)</sup>

<b>Surgical technique</b>
<p>Higher risk of femoral fracture:</p> <ul style="list-style-type: none"> <li>• with cementless techniques than with cemented techniques</li> <li>• with impaction revision THR than with standard revision THR</li> <li>• with press-fit than with exact-fit</li> <li>• with compaction than with broaching</li> <li>• when lack of preoperative templating</li> <li>• when the broach or the prosthesis is driven too far distally</li> <li>• when the broach or the prosthesis is wrongly rotated</li> <li>• with flexible reamer than with non-flexible reamer</li> <li>• when too short or eccentric reaming is performed</li> </ul>
<b>Bone quality</b>
<p>Higher risk of femoral fracture:</p> <ul style="list-style-type: none"> <li>• in revision THR than in primary THR</li> <li>• in female than in male</li> </ul>

femurs. The smooth tamps had a proximal lateral extension which the toothed rasps did not have. As all the fractures were proximal lateral fissures through the greater trochanter, it might be that these fractures were caused by a wedging effect of the lateral proximal tip on the smooth tamps. If this lateral proximal tip on the smooth tamps is removed, the compaction procedure using smooth tamps might be a potentially safe technique with slim AP instrumentation.

The present studies indicate that the fracture pattern is dependent on the design of the instrumentation. Thus, 2/3 of the fractures in the compaction group were located at the calcar region when bulky AP instrumentation was used (I), whereas all fractures were longitudinal fissures through the greater trochanter when slim AP instrumentation was used (II).

Femoral fracture rates of 0.01% to 1.8% have been reported when conventional preparation techniques for cemented THR are used<sup>96;170;188</sup>. In comparison, the fracture rates with smooth tamps developed for cemented THR, producing fractures in six of nine femurs<sup>20</sup> or in eight of 10 femurs (I), seems high. However, high fracture rates with compaction might be expected as the compaction preparation with smooth tamps resembles the impaction technique used in revision arthroplasties<sup>63</sup>, and as high rates (12% - 25%) of intraoperative femoral fracture have been found with the impaction technique<sup>101;106</sup>.

Lower rates of intraoperative femoral fracture have been reported for cemented THR (0.01% - 1.8%)<sup>57;96;170;188</sup> compared with cementless THR (0.2%- 20%)<sup>25;56-58;168;183;193</sup>. In contrast, the femoral fracture rates in the present studies were lower with instruments developed for cementless THR (II) compared with instruments developed for cemented THR (I). However, no comparison of femoral fracture risk in cementless THR versus cemented THR should be made from the two present fracture studies as both the instrumentation and the surgical procedures differed. First, the instrumentation for cemented THR had a more bulky AP appearance compared with the slim AP

instrumentation for cementless THR. Second, the instruments for cemented THR were advanced in single passes whereas the instruments for cementless THR were alternating between a distal and a proximal motion. Finally, the femurs were reamed distally with a flexible reamer before insertion of the cemented instrumentation whereas non-flexible reamers reamed the femurs distally before insertion of cementless instrumentation. Both the bulky AP instrumentation, the flexible reamers, and the single pass surgical technique tend to increase the femoral fracture risk in the study using instrumentation for cemented THR.

The outcome after an intraoperative femoral fracture in THR depends on the location and treatment of the fracture<sup>122</sup>. Thus, if satisfactory initial stability of the implant is obtained, good clinical results can be expected despite intraoperative femoral fracture<sup>122;168;172</sup>. However, femoral fractures are often not detected during surgery<sup>86;168</sup>, and intraoperative femoral fracture may negatively influence the outcome after THR<sup>36;57;58;170;188</sup>. Experimentally, canine studies have demonstrated inferior results when intraoperative femoral fractures occur in conjunction with THR<sup>86;167</sup>. Femoral fractures resulted in ingrowth of fibrous tissue instead of bone ingrowth to the implant<sup>86</sup>, and significantly increased rotational stem instability was found in femurs with a fracture compared with the intact femurs<sup>167</sup>. It therefore seems important to avoid intraoperative femoral fracture. In the present studies, fracture occurred at a significantly greater force than the initial force (I, II). This indicates that the surgeon must become alert to the potential risk of an impending fracture when increasing force is needed to maintain the downward progression of the tamp. The mean forces of 5591 N (I), and of 6248 N (II) needed to produce femoral fractures with smooth tamps in the present studies are slightly lower than a previously found median force of 6531 N needed to initiate a femoral shaft fracture in cementless THR<sup>26</sup>.

DEXA failed to demonstrate differences in BMD changes for Gruen Zones 7B and 7C when single



pass advancement of smooth tamps was compared with single pass advancement of toothed broaches. Even though this nonsignificant result should be interpreted with caution due to low power of the statistical test (small sample of nine pairs), the lack of increments in peri-prosthetic BMD with the smooth tamps suggests that DEXA is not sensitive enough to detect changes in BMD due to the single pass tamping technique.

### **Implant fixation (III - V)**

The present studies add further evidence to the findings that implant fixation is influenced by the surgical technique. Thus, superior implant fixation has been achieved *in vitro* with compaction compared with conventional bone removing techniques<sup>32;34;67;211</sup> (III, IV). Additionally, increased implant fixation has been found *in vivo* with compaction during both non-weight-bearing<sup>67</sup> and weight-bearing<sup>33</sup> (III, IV) conditions.

At time 0, the increment in bone implant contact with compaction was higher for Ti implants inserted exact-fit (440%) (III) than for HA implants inserted press-fit (45%) (IV). Correspondingly, compaction significantly increased peri-implant bone density only around Ti implants inserted exact-fit (III). This indicates that the initial benefits of compaction might be more pronounced for implants inserted with exact-fit compared with press-fit.

By inserting HA coated implants with press-fit, optimal conditions for implant fixation were provided in study IV. Even during these optimal implant conditions, compaction was able to significantly increase ultimate shear strength after 2 weeks of *in vivo* implantation compared with drilling (IV). The effects of compaction was not overpowered by the osteoconductive effects of HA, and thus the compaction technique also seems relevant for insertion of HA coated implants.

At the longest observation time of 4 weeks, the weakest implant fixation was found for Ti implants inserted exact-fit with drilling. Accordingly, at 4 weeks fibrous membranes were only present around Ti implants inserted exact-fit with drilling

(III). For HA implants inserted press-fit no differences existed between compaction and drilling at 4 weeks (IV). A rapid bone turnover in the canine together with optimal conditions for implant fixation might explain why compacted and drilled HA implants were equally fixated after 4 weeks. Vail et al. were unable to show superior fixation with compaction after 12 weeks using HA coated implants in the rabbit<sup>197</sup>.

In addition to being capable of reducing early implant motion, HA coating has also experimentally been shown to reduce migration of polyethylene particles along the bone implant interface<sup>150;151</sup>. This sealing effect could be very important in reducing extension of osteolytic lesions and eventually failure of the implant. It is therefore an important finding that only very little lack of HA coating was observed for both compacted and drilled specimens even though the implants were firmly hammered into the implantation site (IV). Additionally, no delamination of the HA coating was present, which indicates that the lack of HA coating was not a result of mechanical removal. Instead, the lack of HA coating might either be a result of the inability of the plasma-spraying technique to apply HA coating to all areas of a porous coated implant, or a result of biological removal of the HA coating. With a maximum observation time of 4 weeks, it seems most likely that the lack of HA coating was due to the inability of the plasma-spraying technique to apply HA coating to all areas of a porous coated implant

Two different *in vivo* responses have been observed with compaction. Green et al. showed in non-weight-bearing implants, that the difference between compaction and drilling was most pronounced at early time points, and hereafter the difference diminished until significant effects of compaction no longer existed 9 weeks after implantation<sup>67</sup>. A similar response showing significant differences between compaction and drilling at early time periods (0 and 2 weeks), but not at a later time period (4 weeks), was found for weight-bearing HA implants inserted press-fit (IV).

However, for weight-bearing Ti implants inserted exact-fit a biphasic effect of compaction was demonstrated, as compaction provided superior implant fixation at 0 and 4 weeks, but not at 2 weeks (III). This biphasic response indicates that compaction exerts both mechanical and biological effects.

Mechanically, the superior implant fixation found with compaction<sup>32-34;67;211</sup> (III, IV) might be due to spring-back effect of compacted bone (V) resulting in increased frictional forces at the interface between implant and compacted bone. The increased bone-implant contact at time 0 with compaction (III, IV) indicates that a spring-back of compacted bone also occurs in the presence of implants. Clinically, the spring-back of compacted bone might be important to reduce the gaps that often exist initially between the implant and the cancellous bone bed<sup>146;165</sup>. The reduction in gap size might facilitate early bony anchorage of an implant as more extensive and higher organized bony ingrowth has been observed the closer an implant came to initial direct apposition to the bone surface<sup>164</sup>. Additionally, it is important to achieve intimate contact between implant and bone, as finite element analysis has shown that gaps of less than 20  $\mu\text{m}$  between bone and implant substantially can change contact stress distribution<sup>72</sup>. However, in the development of implant designs relying on spring-back of compacted bone it must be considered that the spring-back is neither complete nor symmetrical (V). Furthermore, the spring-back of compacted bone makes it necessary that the implant is inserted immediately after the compaction procedure has been performed.

Biologically, compaction might exert osteoinductive and osteoconductive effects. Osteoinductive growth factors might be released immediately from the compacted bone as compression of cancellous bone has been shown to increase the release of TGF- $\beta$ <sup>60</sup>. TGF- $\beta$ , together with BMPs, which could be released by compaction, has increased bone ingrowth<sup>109;110;186</sup> and mechanical fixation of implants<sup>109;110;111</sup>.

During weight-bearing conditions, load is transferred to the bone implant interface, and reorientation of trabeculae to achieve maximal mechanical effectiveness occurs (Wolff's law)<sup>208</sup>. The increased bone implant contact found at time 0 might be essential for optimal orientation of the peri-implant bone as the implants are weight-loaded.

The high presence of non-vital bone in compacted specimens at 2 weeks (III) probably originated from the breakage and compression of trabeculae during the compaction procedure. Thus, compaction provided an autograft, which may serve as an osteoconductive material for the laying down of new bone. An important effect of the compaction procedure may be that released growth factors are kept within the compressed bone resembling autograft. It has been suggested that osteoinductive factors may only be beneficial for implant fixation when these are mixed with a grafting material functioning as a scaffold or reservoir<sup>89</sup>.

At 2 weeks, the impression was that a high resorptive activity with resorptive lacunae in non vital bone was present around Ti implants inserted with compaction (III). This may explain why no increase in fixation of Ti implants was achieved with compaction at 2 weeks, despite the fact that compaction resulted in increased bone implant contact and peri-implant bone density. High resorptive activity with compaction at 2 weeks might be a result of released growth factors from compacted bone. Thus, growth factors stimulate osteoclasts *in vitro*<sup>92</sup>, and growth factors might be important in the recruitment of osteoclasts<sup>78</sup>. Furthermore, increased peri-implant remodeling and increased bone resorption have been found when growth factors are used alone or in combination with a collagen carrier<sup>88;104;107</sup>. Importantly, the higher resorptive activity found with compaction around Ti implants at 2 weeks did not seem to destabilize the interface between implant and bone. Thus, fixation of Ti implants increased from 2 to 4 weeks in the compaction

group compared with a steady implant fixation from 2 to 4 weeks in drilled specimens (III).

### **Clinical implications of compaction**

In study III and IV, compaction significantly increased push-out parameters by 20 - 433% and histomorphometric bone parameters by 20 - 440% compared with drilling. Two conflicting issues must be addressed when considering whether these increments with compaction might be clinically important. First, the surgical procedures were performed during ideal conditions, and thus it might be that the superior results with the tightly controlled experimental compaction procedure can not be transferred to the clinical situation. On the contrary, it might be that the increased initial implant stability with compaction is more important when implants are inserted into human patients that have inferior healing capacities compared with the young and healthy experimental dog<sup>99</sup>. In the author's opinion, the present studies (III, IV, V), together with previous conducted studies on compaction<sup>32-34;67;211</sup>, provide sufficient evidence to recommend that the compaction technique should be further evaluated in clinical trials. Thus, it is recommended that compaction is tested against conventional femoral preparation techniques in prospective, randomized trials using RSA to detect early implant motion. However, the instrumentations for compaction used in the present femoral fracture studies, should not be used clinically, as too high femoral fracture rates were found (I, II). Study II demonstrated a design deficiency of the slim AP smooth tamp having a proximal, lateral tip which might be responsible for the femoral fractures encountered with the compaction procedure. Thus, the slim AP smooth tamp used in study II has been redesigned to remove this proximal, lateral tip.

At the moment, clinical studies on compaction in THR should be limited to the femoral side. Increased initial implant fixation with compaction has been achieved only when the implantation site has been prepared by compaction of cancellous bone surrounding a preformed canal<sup>132;34;67</sup> (III, IV).

The use of compaction for preparation of a hemispherical site for implantation of an acetabular cup in THR has not been investigated. Theoretically, concerns about the use of compaction at the acetabular side can be raised. Gaps often exist at the polar regions of acetabular cups inserted with press-fit, and the gap increases with increasing degrees of press-fit<sup>98;103;117;118;169</sup>. As compacted bone springs back (V), the use of compaction at the acetabular site might result in insertion of acetabular cups resembling extreme press-fit conditions. Thereby, compaction might increase the risk of large gaps at the polar regions.

Clinically, caution should be made if compaction is used in patients with developmental dysplasia of the hip. These patients often have severe anteversion of the femoral neck<sup>3;155;184</sup>, and it might be problematic to obtain a satisfactory anteversion of the femoral component if smooth tamps are used. The present studies demonstrated that smooth tamps have a tendency to suddenly slip into anteversion as it hit hard cortical bone. In contrast, toothed instruments were able to slice through the cortical bone, thus retaining the correct anteversion during insertion (I, II). At our institution, the maximum femoral neck anteversion that is recommended for compaction with smooth tamps is 25 degrees.

## **Conclusion**

The present studies demonstrated that smooth tamps increased the risk of femoral fracture compared with toothed broaches, when bulky AP instrumentation was used. The risk of femoral fracture with smooth tamps was reduced by slim AP instrumentation. However, even though not statically proven, the femoral fracture rate with slim AP instrumentation was still considerable higher with compaction compared with conventional rasping. We find that a proximal lateral extension on the slim AP smooth tamps, which was not present on the rasps, was responsible for the fissures through the greater trochanter encountered with slim AP smooth tamps.

*In vivo*, compaction yielded superior implant fixation compared with drilling for both Ti implants inserted exact-fit and for HA implants inserted press-fit. For HA implants, the superior effects of compaction was present at 0 and 2, but not at 4 weeks. In contrast, for Ti implants, a biphasic response of compaction was observed, as superior implant fixation existed in compacted specimens at 0 and 4 weeks, but not at 2 weeks. This biphasic response indicates that compaction exerts both mechanical and biological effects. A spring-back effect, which was demonstrated *in vivo* of compacted bone, offers a possible explanation for the superior implant fixation found with compaction.

## ***Suggestions for future research***

In study I, it was shown that preparation of the proximal femur with single pass advancement of smooth tamps increased the risk of femoral fracture without leading to significant increases in periprosthetic BMD for Gruen Zones 7B and 7C compared with single pass advancement of toothed broaches. Additional studies should investigate whether toothed broaches inserted with the single pass technique could be associated with the same increase in implant stability previously observed for femurs prepared with smooth tamps using the single pass technique. There are different instrumentation methods to achieve radial cancellous compaction of existing bone. Additional research aimed at reducing the risk of femoral fracture during compaction, while maintaining the benefits of the resulting increased postoperative implant stability, is required. The risk of femoral fracture with compaction might be reduced by prophylactic cable wiring of the proximal femur<sup>80</sup> or by use of a pneumatic power-tool to advance the tamps with a controlled impulse.

As gaps often initially exist around implants<sup>146,165</sup> it would be of interest to test whether the spring-back of compacted bone would provide superior *in vivo* fixation of implants inserted with a surrounding gap to cancellous bone.

For Ti implants, qualitative differences in resorptive activity were found between compacted and drilled specimens. Studies with longer follow-up time than 4 weeks are therefore warranted. Additionally, it could be interesting to investigate whether further increments in fixation with compaction can be achieved in implants immobilized with a substrate that exerts adverse effects on bone resorption. This could for example be implants immobilized with bisphosphonates<sup>210</sup>.

For HA implants at 4 weeks, we found that the peri-implant bony tissue of drilled and compacted specimens having a high bone implant contact mainly consisted of non-vital and compressed lamellar bone. Therefore, it would be interesting to perform a longer-term study comparing compaction with drilling after this compressed bone has undergone remodeling in weight-bearing conditions.

The bony fixation of Ti implants has been weakened by the presence of experimentally induced osteopenia<sup>177</sup>. As many patients with joint disease have a deficient bone stock as seen in osteoporosis, prolonged steroid treatment, and rheumatoid arthritis, it would be of interest to investigate whether compaction is able to increase implant fixation in osteopenic bone. Moreover, the compaction technique might be useful for insertion of an implant into the extensive cancellous bone of the femoral neck in femoral neck preserving THR.

In addition to THR, the compaction technique might also be beneficial for insertion of implants into other areas with cancellous bone such as replacements of the knee, shoulder, and elbow.

Finally, the compaction technique must be compared with conventional femoral preparation techniques in randomized, prospective studies using RSA before the compaction technique can be recommended for general use.

---

**References**

1. Aerssens J, Boonen S, Lowet G, and Dequeker J. Interspecies differences in bone composition, density, and quality: potential implications for in vivo bone research. *Endocrinology* 1998;139:663-70.
2. Altman DG. Practical Statistics for Medical Research. 8 ed. Chapman and Hall/CRC, 1999:126.
3. Anda S, Terjesen T, Kvistad KA, and Svenningsen S. Acetabular angles and femoral anteversion in dysplastic hips in adults: CT investigation. *J.Comput.Assist.Tomogr.* 1991;15:115-20.
4. Aspenberg P and Astrand J. Bone allografts pretreated with a bisphosphonate are not resorbed. *Acta Orthop Scand.* 2002;73:20-3.
5. Astrand J and Aspenberg P. Reduction of instability-induced bone resorption using bisphosphonates: high doses are needed in rats. *Acta Orthop Scand.* 2002;73:24-30.
6. Bargar WL. Shape the implant to the patient. A rationale for the use of custom-fit cementless total hip implants. *Clin.Orthop* 1989;73-8.
7. Bargar WL, Bauer A, and Borner M. Primary and revision total hip replacement using the Robodoc system. *Clin.Orthop* 1998;82-91.
8. Barth E, Ronningen H, Solheim LF, and Saethren B. Bone ingrowth into weight-bearing porous fiber titanium implants. Mechanical and biochemical correlations. *J Orthop.Res.* 1986;4:356-61.
9. Bauer TW, Geesink RC, Zimmerman R, and McMahon JT. Hydroxyapatite-coated femoral stems. Histological analysis of components retrieved at autopsy. *J Bone Joint Surg.Am.* 1991;73:1439-52.
10. Bauer TW, Stulberg BN, Ming J, and Geesink RG. Uncemented acetabular components. Histologic analysis of retrieved hydroxyapatite-coated and porous implants. *J Arthroplasty* 1993;8:167-77.
11. Bechtold, J., Mouzin, O., Chen, X., and Soballe, K. Relative effects of alendronate and implant motion on revision implant fixation. *Trans Orthop Res Soc* 26, 2001.
12. Berry DJ. Epidemiology: hip and knee. *Orthop.Clin.North Am.* 1999;30:183-90.
13. Bert JM. Custom total hip arthroplasty. *J Arthroplasty* 1996;11:905-15.
14. Berzins A, Shah B, Weinans H, and Sumner DR. Nondestructive measurements of implant-bone interface shear modulus and effects of implant geometry in pull-out tests. *J.Biomed.Mater.Res.* 1997;34:337-40.
15. Bobynd JD, Pilliar RM, Cameron HU, and Weatherly GC. The optimum pore size for the fixation of porous-surfaced metal implants by the ingrowth of bone. *Clin.Orthop* 1980;263-70.
16. Boettcher WG. Total hip arthroplasties in the elderly. Morbidity, mortality, and cost effectiveness. *Clin.Orthop* 1992;30-4.
17. Bostrom MP. Expression of bone morphogenetic proteins in fracture healing. *Clin.Orthop.* 1998;S116-S123.
18. Bragdon CR, Burke D, Lowenstein JD et al. Differences in stiffness of the interface between a cementless porous implant and cancellous bone in vivo in dogs due to varying amounts of implant motion. *J.Arthroplasty* 1996;11:945-51.
19. Branemark R, Ohnells LO, Nilsson P, and Thomsen P. Biomechanical characterization of osseointegration during healing: an experimental in vivo study in the rat. *Biomaterials* 1997;18:969-78.
20. Breusch SJ, Norman TL, Revie IC et al. Cement penetration in the proximal femur does not depend on broach surface finish. *Acta Orthop Scand.* 2001;72:29-35.
21. Brown TD and Ferguson AB, Jr. Mechanical property distributions in the cancellous bone of the human proximal femur. *Acta Orthop.Scand.* 1980;51:429-37.
22. Cameron HU, Pilliar RM, and Macnab I. The effect of movement on the bonding of porous metal to bone. *J Biomed.Mater.Res* 1973;7:301-11.
23. Campbell, Canale ST. *Operative Orthopaedics.* Ninth ed. Mosby-Year Book, Inc., 1998.
24. Canalis E, McCarthy T, and Centrella M. Growth factors and the regulation of bone remodeling. *J Clin.Invest* 1988;81:277-81.
25. Capello WN, Sallay PI, and Feinberg JR. Omniflex modular femoral component. Two- to five-year results. *Clin.Orthop.* 1994;54-9.
26. Carls J, Kohn D, and Rossig S. A comparative study of two cerclage systems. *Arch.Orthop.Trauma.Surg.* 1999;119:67-72.
27. Carlsson L, Rostlund T, Albrektsson B, and Albrektsson T. Implant fixation improved by close fit. Cylindrical implant-bone interface studied in rabbits. *Acta Orthop Scand.* 1988;59:272-5.
28. Carter DR and Spengler DM. Mechanical properties and composition of cortical bone. *Clin.Orthop.* 1978;192-217.

## References

---

29. Carter LW, Stovall DO, and Young TR. Determination of accuracy of preoperative templating of noncemented femoral prostheses. *J.Arthroplasty* 1995;10:507-13.
30. Centrella M, McCarthy TL, and Canalis E. Effects of transforming growth factors on bone cells. *Connect.Tissue Res* 1989;20:267-75.
31. Chandler HP, Ayres DK, Tan RC, Anderson LC, and Varma AK. Revision total hip replacement using the S-ROM femoral component. *Clin.Orthop* 1995;130-40.
32. Channer MA, Glisson RR, Seaber AV, and Vail TP. Use of bone compaction in total knee arthroplasty. *J.Arthroplasty* 1996;11:743-9.
33. Chareancholvanich, K., Bechtold, J., Soballe, K., Lew, W, and Gustilo, R. Compaction of existing cancellous bone in the primary setting enhances interfacial shear strength in vivo. *Trans Orthop Res Soc* 24, 1999.
34. Chareancholvanich K, Bourgeault C, Schmidt AH, Gustilo R, and Lew W. In Vitro Stability of Cemented and Cementless Femoral Stems With Compaction. *Clin.Orthop* 2002;290-302.
35. Checovich, M. M., Kiratli, B. J., Heiner, J. P., Wilson, M. A., and McBeath, A. A. Quantifying bone loss after cementless total hip arthroplasty. *Trans Orthop Res Soc* 21, 1994.
36. Christensen CM, Seger BM, and Schultz RB. Management of intraoperative femur fractures associated with revision hip arthroplasty. *Clin.Orthop.* 1989;177-80.
37. Christensen FB, Dalstra M, Sejling F, Overgaard S, and Bunker C. Titanium-alloy enhances bone-pedicle screw fixation: mechanical and histomorphometrical results of titanium-alloy versus stainless steel. *Eur.Spine J.* 2000;9:97-103.
38. Ciccotti MG, Rothman RH, Hozack WJ, and Moriarty L. Clinical and roentgenographic evaluation of hydroxyapatite-augmented and nonaugmented porous total hip arthroplasty. *J Arthroplasty* 1994;9:631-9.
39. Claes LE, Wilke HJ, and Kiefer H. Osteonal structure better predicts tensile strength of healing bone than volume fraction. *J Biomech.* 1995;28:1377-90.
40. Coathup MJ, Blunn GW, Flynn N, Williams C, and Thomas NP. A comparison of bone remodelling around hydroxyapatite-coated, porous-coated and grit-blasted hip replacements retrieved at post-mortem. *J Bone Joint Surg.Br.* 2001;83:118-23.
41. Cochran GVB. *Orthopädische Biomechanik.* Enke, Stuttgart. 1988.
42. Cohen B and Rushton N. Accuracy of DEXA measurement of bone mineral density after total hip arthroplasty. *J Bone Joint Surg.Br.* 1995;77:479-83.
43. Collier JP, Bauer TW, Bloebaum RD et al. Results of implant retrieval from postmortem specimens in patients with well-functioning, long-term total hip replacement. *Clin.Orthop* 1992;97-112.
44. Cook SD, Thomas KA, Kay JF, and Jarcho M. Hydroxyapatite-coated porous titanium for use as an orthopedic biologic attachment system. *Clin.Orthop* 1988;303-12.
45. Cushner F and Friedman RJ. Economic impact of total hip arthroplasty. *South.Med.J* 1988;81:1379-81.
46. de Groot K, Geesink R, Klein CP, and Serekian P. Plasma sprayed coatings of hydroxylapatite. *J Biomed.Mater.Res* 1987;21:1375-81.
47. Dhert WJ, Thomsen P, Blomgren AK, Esposito M, Ericson LE, and Verbout AJ. Integration of press-fit implants in cortical bone: a study on interface kinetics. *J Biomed.Mater.Res* 1998;41:574-83.
48. Dhert WJ, Verheyen CC, Braak LH et al. A finite element analysis of the push-out test: influence of test conditions. *J Biomed.Mater.Res* 1992;26:119-30.
49. Ding M, Danielsen CC, and Hvid I. Bone density does not reflect mechanical properties in early-stage arthrosis. *Acta Orthop Scand.* 2001;72:181-5.
50. Dreghorn CR and Hamblen DL. Revision arthroplasty: a high price to pay. *BMJ* 1989;298:648-9.
51. Ducheyne P, De Meester P, and Aernoudt E. Influence of a functional dynamic loading on bone ingrowth into surface pores of orthopedic implants. *J.Biomed.Mater.Res.* 1977;11:811-38.
52. Einhorn TA. Enhancement of fracture-healing. *J Bone Joint Surg.Am.* 1995;77:940-56.
53. Einhorn TA. The cell and molecular biology of fracture healing. *Clin.Orthop* 1998;S7-21.
54. Elias JJ, Nagao M, Chu YH, Carbone JJ, Lennox DW, and Chao EY. Medial cortex strain distribution during noncemented total hip arthroplasty. *Clin.Orthop.* 2000;250-8.
55. Fadda M, Marcacci M, Toksvig-Larsen S, Wang T, and Meneghello R. Improving accuracy of bone resections using robotics tool holder and a high speed milling cutting tool. *J Med.Eng Technol.* 1998;22:280-4.
56. Falez F, Santori N, and Panegrossi G. Intraoperative type 1 proximal femoral fractures:

## References

---

- influence on the stability of hydroxyapatite-coated femoral components. *J.Arthroplasty* 1998;13:653-9.
57. Federici A, Carbone M, and Sanguineti F. Intraoperative fractures of the femoral diaphysis in hip arthroprosthesis surgery. *Ital.J.Orthop.Traumatol.* 1988;14:311-21.
58. Fitzgerald RHJ, Brindley GW, and Kavanagh BF. The uncemented total hip arthroplasty. Intraoperative femoral fractures. *Clin.Orthop.* 1988;61-6.
59. Furnes A, Lie SA, Havelin LI, Engesaeter LB, and Vollset SE. The economic impact of failures in total hip replacement surgery: 28,997 cases from the Norwegian Arthroplasty Register, 1987-1993. *Acta Orthop Scand.* 1996;67:115-21.
60. Fyhrie D., Yeni Y., Lin D. Li, and Gibson G. Mechanical stress driven release of TGF Beta2 from mineralized cancellous bone. *Trans Orthop Res Soc* 26, 2001.
61. Galante J, Rostoker W, and Ray RD. Physical properties of trabecular bone. *Calcif.Tissue Res.* 1970;5:236-46.
62. Geesink RG, de Groot K, and Klein CP. Chemical implant fixation using hydroxyl-apatite coatings. The development of a human total hip prosthesis for chemical fixation to bone using hydroxyl-apatite coatings on titanium substrates. *Clin.Orthop* 1987;147-70.
63. Gie GA, Linder L, Ling RS, Simon JP, Slooff TJ, and Timperley AJ. Impacted cancellous allografts and cement for revision total hip arthroplasty. *J.Bone Joint Surg.Br.* 1993;75:14-21.
64. Goldstein SA, Matthews LS, Kuhn JL, and Hollister SJ. Trabecular bone remodeling: an experimental model. *J.Biomech.* 1991;24 Suppl 1:135-50.
65. Gotfredsen K, Budtz-Jorgensen E, and Jensen LN. A method for preparing and staining histological sections containing titanium implants for light microscopy. *Stain Technol.* 1989;64:121-7.
66. Gotfredsen K, Wennerberg A, Johansson C, Skovgaard LT, and Hjorting-Hansen E. Anchorage of TiO<sub>2</sub>-blasted, HA-coated, and machined implants: an experimental study with rabbits. *J.Biomed.Mater.Res.* 1995;29:1223-31.
67. Green JR, Nemzek JA, Arnoczky SP, Johnson LL, and Balas MS. The effect of bone compaction on early fixation of porous-coated implants. *J.Arthroplasty* 1999;14:91-7.
68. Gruen TA, McNeice GM, and Amstutz HC. "Modes of failure" of cemented stem-type femoral components: a radiographic analysis of loosening. *Clin.Orthop* 1979;17-27.
69. Guldberg RE, Caldwell NJ, Guo XE, Goulet RW, Hollister SJ, and Goldstein SA. Mechanical stimulation of tissue repair in the hydraulic bone chamber. *J Bone Miner.Res* 1997;12:1295-302.
70. Gundersen HJ, Bendtsen TF, Korbo L et al. Some new, simple and efficient stereological methods and their use in pathological research and diagnosis. *APMIS* 1988;96:379-94.
71. Haentjens P, De Boeck H, and Opdecam P. Proximal femoral replacement prosthesis for salvage of failed hip arthroplasty: complications in a 2-11 year follow-up study in 19 elderly patients. *Acta Orthop Scand.* 1996;67:37-42.
72. Harrigan TP and Harris WH. A finite element study of the effect of diametral interface gaps on the contact areas and pressures in uncemented cylindrical femoral total hip components. *J Biomech.* 1991;24:87-91.
73. Harrigan TP, Kareh J, and Harris WH. The influence of support conditions in the loading fixture on failure mechanisms in the push-out test: a finite element study. *J Orthop Res* 1990;8:678-84.
74. Hart, R., Janecek, M., and Bucek, P. Implantation of the acetabular cup with the use of the CT-free navigation. *Proceedings from the European Hip Society Domestic Meeting 2002, in Hip International* 12(2), 252, 2002.
75. Havelin LI, Engesaeter LB, Espehaug B, Furnes O, Lie SA, and Vollset SE. The Norwegian Arthroplasty Register: 11 years and 73,000 arthroplasties. *Acta Orthop.Scand.* 2000;71:337-53.
76. Head WC, Bauk DJ, and Emerson RH, Jr. Titanium as the material of choice for cementless femoral components in total hip arthroplasty. *Clin.Orthop* 1995;85-90.
77. Heck DA, Nakajima I, Kelly PJ, and Chao EY. The effect of load alteration on the biological and biomechanical performance of a titanium fiber-metal segmental prosthesis. *J.Bone Joint Surg.Am.* 1986;68:118-26.
78. Hentunen TA, Lakkakorpi PT, Tuukkanen J, Lehenkari PP, Sampath TK, and Vaananen HK. Effects of recombinant human osteogenic protein-1 on the differentiation of osteoclast-like cells and bone resorption. *Biochem.Biophys.Res.Commun.* 1995;209:433-43.



## References

---

79. Herberts P and Malchau H. Long-term registration has improved the quality of hip replacement: a review of the Swedish THR Register comparing 160,000 cases. *Acta Orthop Scand.* 2000;71:111-21.
80. Herzwurm PJ, Walsh J, Pettine KA, and Ebert FR. Prophylactic cerclage: a method of preventing femur fracture in uncemented total hip arthroplasty. *Orthopedics* 1992;15:143-6.
81. Hollister SJ, Guldberg RE, Kuelske CL, Caldwell NJ, Richards M, and Goldstein SA. Relative effects of wound healing and mechanical stimulus on early bone response to porous-coated implants. *J Orthop Res* 1996;14:654-62.
82. Huiskes R. Failed innovation in total hip replacement. Diagnosis and proposals for a cure. *Acta Orthop Scand.* 1993;64:699-716.
83. Incavo SJ, DiFazio F, Wilder D, Howe JG, and Pope M. Longitudinal crack propagation in bone around femoral prosthesis [see comments]. *Clin.Orthop.* 1991;175-80.
84. Jantsch S, Leixnering M, Schwagerl W, and Hackl H. Shaft fissures due to implantation of cementless total endoprostheses of the hip joint. An experimental study. *Arch.Orthop.Trauma Surg.* 1988;107:236-41.
85. Jasty M, Bragdon C, Burke D, O'Connor D, Lowenstein J, and Harris WH. In vivo skeletal responses to porous-surfaced implants subjected to small induced motions. *J Bone Joint Surg.Am.* 1997;79:707-14.
86. Jasty M, Bragdon CR, Rubash H, Schutzer SF, Haire T, and Harris W. Unrecognized femoral fractures during cementless total hip arthroplasty in the dog and their effect on bone ingrowth. *J.Arthroplasty* 1992;7:501-8.
87. Jasty M, Henshaw RM, O'Connor DO, and Harris WH. High assembly strains and femoral fractures produced during insertion of uncemented femoral components. A cadaver study. *J Arthroplasty* 1993;8:479-87.
88. Jensen TB, Overgaard S, Lind M, Rahbek O, Bunger C, and Soballe K. Osteogenic protein 1 device increases bone formation and bone graft resorption around cementless implants. *Acta Orthop Scand.* 2002;73:31-9.
89. Jensen TB, Soballe K, and Bechtold J. Autologous growth factor (AGF) mixed with allograft increases fixation of cementless implants: An experimental dog study. *Proceedings from the European Hip Society 2002 Domestic Meeting, in Hip International* 12, 2002.
90. Jin Y, Yang L, and White FH. An immunocytochemical study of bone morphogenetic protein in experimental fracture healing of the rabbit mandible. *Chin.Med.Sci.J.* 1994;9:91-5.
91. Johansson JE, McBroom R, Barrington TW, and Hunter GA. Fracture of the ipsilateral femur in patients with total hip replacement. *J.Bone Joint Surg. Am.* 1981;63:1435-42.
92. Kanatani M, Sugimoto T, Kaji H et al. Stimulatory effect of bone morphogenetic protein-2 on osteoclast-like cell formation and bone-resorbing activity. *J.Bone Miner.Res.* 1995;10:1681-90.
93. Karrholm J, Anderber C, Snorrason F et al. Evaluation of a femoral stem with reduced stiffness. A randomized study with use of radiostereometry and bone densitometry. *J.Bone Joint Surg.Am.* 2002;84:1651-8.
94. Karrholm J, Herberts P, Hultmark P, Malchau H, Nivbrant B, and Thanner J. Radiostereometry of hip prostheses. Review of methodology and clinical results. *Clin.Orthop* 1997;94-110.
95. Karrholm J, Malchau H, Snorrason F, and Herberts P. Micromotion of femoral stems in total hip arthroplasty. A randomized study of cemented, hydroxyapatite-coated, and porous-coated stems with roentgen stereophotogrammetric analysis. *J Bone Joint Surg.Am.* 1994;76:1692-705.
96. Khan MA and O'Driscoll M. Fractures of the femur during total hip replacement and their management. *J.Bone Joint Surg.Br.* 1977;59:36-41.
97. Kienapfel H, Sumner DR, Turner TM, Urban RM, and Galante JO. Efficacy of autograft and freeze-dried allograft to enhance fixation of porous coated implants in the presence of interface gaps. *J Orthop.Res.* 1992;10:423-33.
98. Kim YS, Brown TD, Pedersen DR, and Callaghan JJ. Reamed surface topography and component seating in press-fit cementless acetabular fixation. *J Arthroplasty* 1995;10 Suppl:S14-S21.
99. Kimmel DB and Jee WS. A quantitative histologic study of bone turnover in young adult beagles. *Anat.Rec.* 1982;203:31-45.
100. Kiratli BJ, Heiner JP, McBeath AA, and Wilson MA. Determination of bone mineral density by dual x-ray absorptiometry in patients with uncemented total hip arthroplasty. *J Orthop Res* 1992;10:836-44.
101. Knight JL and Helming C. Collarless polished tapered impaction grafting of the femur during

## References

---

- revision total hip arthroplasty: pitfalls of the surgical technique and follow-up in 31 cases. *J Arthroplasty* 2000;15:159-65.
102. Kroger H, Miettinen H, Arnala I, Koski E, Rushton N, and Suomalainen O. Evaluation of periprosthetic bone using dual-energy x-ray absorptiometry: precision of the method and effect of operation on bone mineral density. *J Bone Miner Res* 1996;11:1526-30.
103. Kwong LM, O'Connor DO, Sedlacek RC, Krushell RJ, Maloney WJ, and Harris WH. A quantitative in vitro assessment of fit and screw fixation on the stability of a cementless hemispherical acetabular component. *J Arthroplasty* 1994;9:163-70.
104. Laursen M, Hoy K, Hansen ES, Gelineck J, Christensen FB, and Bunger CE. Recombinant bone morphogenetic protein-7 as an intracorporal bone growth stimulator in unstable thoracolumbar burst fractures in humans: preliminary results. *Eur.Spine J.* 1999;8:485-90.
105. Lavernia CJ, Drakeford MK, Tsao AK, Gittelsohn A, Krackow KA, and Hungerford DS. Revision and primary hip and knee arthroplasty. A cost analysis. *Clin.Orthop* 1995;136-41.
106. Leopold SS, Berger RA, Rosenberg AG, Jacobs JJ, Quigley LR, and Galante JO. Impaction allografting with cement for revision of the femoral component. A minimum four-year follow-up study with use of a precoated femoral stem. *J Bone Joint Surg.Am.* 1999;81:1080-92.
107. Lind M, Overgaard S, Glerup H, Soballe K, and Bunger C. Transforming growth factor-beta1 adsorped to tricalciumphosphate coated implants increases peri-implant bone remodeling. *Biomaterials* 2001;22:189-93.
108. Lind M, Overgaard S, Jensen TB et al. Effect of osteogenic protein 1/collagen composite combined with impacted allograft around hydroxyapatite-coated titanium alloy implants is moderate. *J Biomed.Mater.Res.* 2001;55:89-95.
109. Lind M, Overgaard S, Nguyen T, Ongpipattanakul B, Bunger C, and Soballe K. Transforming growth factor-beta stimulates bone ongrowth. Hydroxyapatite-coated implants studied in dogs. *Acta Orthop.Scand.* 1996;67:611-6.
110. Lind M, Overgaard S, Ongpipattanakul B, Nguyen T, Bunger C, and Soballe K. Transforming growth factor-beta 1 stimulates bone ongrowth to weight- loaded tricalcium phosphate coated implants: an experimental study in dogs. *J Bone Joint Surg.Br.* 1996;78:377-82.
111. Lind M, Overgaard S, Soballe K, Nguyen T, Ongpipattanakul B, and Bunger C. Transforming growth factor-beta 1 enhances bone healing to unloaded tricalcium phosphate coated implants: an experimental study in dogs. *J Orthop Res* 1996;14:343-50.
112. Lind M, Overgaard S, Song Y, Goodman SB, Bunger C, and Soballe K. Osteogenic protein 1 device stimulates bone healing to hydroxyapatite- coated and titanium implants. *J Arthroplasty* 2000;15:339-46.
113. Lind M, Soballe K, Overgaard S, Werle J, Goodman S, and Bunger C. Stimulated Bone Healing. *Critical Reviews in Physical and Rehabilitation Medicine* 2000;12:313-43.
114. Linde F. Elastic and viscoelastic properties of trabecular bone by a compression testing approach. *Dan.Med.Bull.* 1994;41:119-38.
115. Linde F and Sorensen HC. The effect of different storage methods on the mechanical properties of trabecular bone. *J.Biomech.* 1993;26:1249-52.
116. Lucht U. The Danish Hip Arthroplasty Register. *Acta Orthop Scand.* 2000;71:433-9.
117. Macdonald W, Carlsson LV, Charnley GJ, Jacobsson CM, and Johansson CB. Inaccuracy of acetabular reaming under surgical conditions. *J.Arthroplasty* 1999;14:730-7.
118. MacKenzie JR, Callaghan JJ, Pedersen DR, and Brown TD. Areas of contact and extent of gaps with implantation of oversized acetabular components in total hip arthroplasty. *Clin.Orthop* 1994;127-36.
119. Malchau H, Herberts P, and Ahnfelt L. Prognosis of total hip replacement in Sweden. Follow-up of 92,675 operations performed 1978-1990. *Acta Orthop Scand.* 1993;64:497-506.
120. Malchau, H., Herberts, P., Soderman, P, and Oden, A. Prognosis of Total Hip Replacement; Update and Validation of Results from the Swedish National Hip Arthroplasty Register 1979-1998. *Scientific Exhibition presented at 67<sup>th</sup> Annual Meeting of the American Association of Orthopaedic Surgeons* 2000.
121. Malkani AL, Lewallen DG, Cabanela ME, and Wallrichs SL. Femoral component revision using an uncemented, proximally coated, long-stem prosthesis. *J Arthroplasty* 1996;11:411-8.
122. Mallory TH, Kraus TJ, and Vaughn BK. Intraoperative femoral fractures associated with cementless total hip arthroplasty. *Orthopedics* 1989;12:231-9.

## References

---

123. Martelli M, Marcacci M, Nofrini L et al. Computer- and robot-assisted total knee replacement: analysis of a new surgical procedure. *Ann.Biomed.Eng* 2000;28:1146-53.
124. Marx RE, Carlson ER, Eichstaedt RM, Schimmele SR, Strauss JE, and Georgeff KR. Platelet-rich plasma: Growth factor enhancement for bone grafts. *Oral Surg.Oral Med.Oral Pathol.Oral Radiol.Endod.* 1998;85:638-46.
125. McCarthy JC, Bono JV, and O'Donnell PJ. Custom and modular components in primary total hip replacement. *Clin.Orthop* 1997;162-71.
126. McKibbin B. The biology of fracture healing in long bones. *J Bone Joint Surg.Br.* 1978;60-B:150-62.
127. Meding JB, Ritter MA, Keating EM, and Faris PM. Impaction bone-grafting before insertion of a femoral stem with cement in revision total hip arthroplasty. A minimum two-year follow-up study. *J Bone Joint Surg.Am.* 1997;79:1834-41.
128. Millett PJ, Allen MJ, and Bostrom MP. Effects of alendronate on particle-induced osteolysis in a rat model. *J Bone Joint Surg.Am.* 2002;84-A:236-49.
129. Moroni A, Faldini C, Piras F, and Giannini S. Risk factors for intraoperative femoral fractures during total hip replacement. *Ann.Chir Gynaecol.* 2000;89:113-8.
130. Morrey BF and Kavanagh BF. Complications with revision of the femoral component of total hip arthroplasty. Comparison between cemented and uncemented techniques. *J Arthroplasty* 1992;7:71-9.
131. Mortimer ES, Rosenthal L, Paterson I, and Bobyn JD. Effect of rotation on periprosthetic bone mineral measurements in a hip phantom. *Clin.Orthop* 1996;269-74.
132. Mouzin O, Soballe K, and Bechtold JE. Loading improves anchorage of hydroxyapatite implants more than titanium implants. *J Biomed.Mater.Res* 2001;58:61-8.
133. Murphy, S. and Deshmukh, R. Applications of surgical navigation to primary total hip arthroplasty. *Proceedings from the European Hip Society Domestic Meeting 2002, in Hip International* 12(2), 2002.
134. Nakase T, Nomura S, Yoshikawa H et al. Transient and localized expression of bone morphogenetic protein 4 messenger RNA during fracture healing. *J.Bone Miner.Res.* 1994;9:651-9.
135. Nelissen RG, Valstar ER, and Rozing PM. The effect of hydroxyapatite on the micromotion of total knee prostheses. A prospective, randomized, double-blind study. *J Bone Joint Surg.Am.* 1998;80:1665-72.
136. Noble PC, Alexander JW, Lindahl LJ, Yew DT, Granberry WM, and Tullos HS. The anatomic basis of femoral component design *Clin.Orthop* 1988;148-65.
137. Nordsletten, L., Aamodt, A., Benum, P., and Grant, P. Small differences in stability between the Scandinavian Customized Prosthesis (SCP) and the cemented Elite-Plus femoral stem. A randomized prospective study with radiostereometric 1-year follow-up. *Proceedings from the European Hip Society Domestic Meeting, 2002, in Hip International* 12(2), 2002.
138. Onsten I, Nordqvist A, Carlsson AS, Besjakov J, and Shott S. Hydroxyapatite augmentation of the porous coating improves fixation of tibial components. A randomised RSA study in 116 patients. *J Bone Joint Surg.Br.* 1998;80:417-25.
139. Otani T, Whiteside LA, White SE, and McCarthy DS. Reaming technique of the femoral diaphysis in cementless total hip arthroplasty. *Clin.Orthop.* 1995;210-21.
140. Overgaard S. Calcium phosphate coatings for fixation of implants. *Acta Orthop Scand.Suppl.* 2000;71:1-74.
141. Overgaard S, Bromose U, Lind M, Bunger C, and Soballe K. The influence of crystallinity of the hydroxyapatite coating on the fixation of implants. Mechanical and histomorphometric results. *J Bone Joint Surg.Br.* 1999;81:725-31.
142. Overgaard S, Lind M, Glerup H, Bunger C, and Soballe K. Porous-coated versus grit-blasted surface texture of hydroxyapatite-coated implants during controlled micromotion: mechanical and histomorphometric results. *J Arthroplasty* 1998;13:449-58.
143. Overgaard S, Lind M, Rahbek O, Bunger C, and Soballe K. Improved fixation of porous-coated versus grit-blasted surface texture of hydroxyapatite-coated implants in dogs. *Acta Orthop Scand.* 1997;68:337-43.
144. Overgaard S, Soballe K, Jorgen H, and Gundersen G. Efficiency of systematic sampling in histomorphometric bone research illustrated by hydroxyapatite-coated implants: optimizing the stereological vertical-section design. *J Orthop Res* 2000;18:313-21.
145. Park JY, Gemmell CH, and Davies JE. Platelet interactions with titanium: modulation of platelet activity by surface topography. *Biomaterials* 2001;22:2671-82.

## References

---

146. Paul HA, Bargar WL, Mittlestadt B et al. Development of a surgical robot for cementless total hip arthroplasty. *Clin.Orthop.* 1992;57-66.
147. Pekkarinen J, Alho A, Lepisto J, Ylikoski M, Ylinen P, and Paavilainen T. Impaction bone grafting in revision hip surgery. A high incidence of complications. *J.Bone Joint Surg.Br.* 2000;82:103-7.
148. Pilliar RM, Lee JM, and Maniopoulos C. Observations on the effect of movement on bone ingrowth into porous- surfaced implants. *Clin.Orthop* 1986;108-13.
149. Pope MH and Outwater JO. The fracture characteristic of bone substance. *J.Biomech.* 1972;5:457-65.
150. Rahbek O, Overgaard S, Lind M, Bendix K, Bunker C, and Soballe K. Sealing effect of hydroxyapatite coating on peri-implant migration of particles. An experimental study in dogs. *J Bone Joint Surg.Br.* 2001;83:441-7.
151. Rahbek O, Overgaard S, Soballe K, Bendix K, and Soballe K. Sealing effect of hydroxyapatite coating; A 12 month study in canines. *Acta Orthop Scand.* 2000;71:563-73.
152. Ramamurti BS, Orr TE, Bragdon CR, Lowenstein JD, Jasty M, and Harris WH. Factors influencing stability at the interface between a porous surface and cancellous bone: a finite element analysis of a canine in vivo micromotion experiment. *J Biomed.Mater.Res* 1997;36:274-80.
153. Reddi AH, Wientroub S, and Muthukumar N. Biologic principles of bone induction. *Orthop Clin.North Am.* 1987;18:207-12.
154. Regner L, Carlsson L, Karrholm J, and Herberts P. Tibial component fixation in porous- and hydroxyapatite-coated total knee arthroplasty: a radiostereo metric evaluation of migration and inducible displacement after 5 years. *J Arthroplasty* 2000;15:681-9.
155. Robertson DD, Essinger JR, Imura S et al. Femoral deformity in adults with developmental hip dysplasia. *Clin.Orthop* 1996;196-206.
156. Robinson TM, Kruse-Elliott KT, Markel MD, Pluhar GE, Massa K, and Bjorling DE. A comparison of transdermal fentanyl versus epidural morphine for analgesia in dogs undergoing major orthopedic surgery. *J.Am.Anim Hosp.Assoc.* 1999;35:95-100.
157. Ruegsegger P, Koller B, and Muller R. A microtomographic system for the nondestructive evaluation of bone architecture. *Calcif.Tissue Int.* 1996;58:24-9.
158. Russ JC. Image measurements. In: Russ JC, ed. *Computer-assisted microscopy. The measurement and analysis of images.* First ed. New York: Plenum Press, 1990:175-220.
159. Russell RG and Rogers MJ. Bisphosphonates: from the laboratory to the clinic and back again. *Bone* 1999;25:97-106.
160. Ryd L, Albrektsson BE, Carlsson L et al. Roentgen stereophotogrammetric analysis as a predictor of mechanical loosening of knee prostheses. *J Bone Joint Surg.Br.* 1995;77:377-83.
161. Sabo D, Reiter A, Simank HG, Thomsen M, Lukoschek M, and Ewerbeck V. Periprosthetic mineralization around cementless total hip endoprosthesis: longitudinal study and cross-sectional study on titanium threaded acetabular cup and cementless Spotorno stem with DEXA. *Calcif.Tissue Int.* 1998;62:177-82.
162. Sabokbar A, Fujikawa Y, Murray DW, and Athanasou NA. Bisphosphonates in bone cement inhibit PMMA particle induced bone resorption. *Ann.Rheum.Dis.* 1998;57:614-8.
163. Sandberg MM. Matrix in cartilage and bone development: current views on the function and regulation of major organic components. *Ann.Med.* 1991;23:207-17.
164. Sandborn PM, Cook SD, Spires WP, and Kester MA. Tissue response to porous-coated implants lacking initial bone apposition. *J Arthroplasty* 1988;3:337-46.
165. Schimmel JW and Huiskes R. Primary fit of the Lord cementless total hip. A geometric study in cadavers. *Acta Orthop.Scand.* 1988;59:638-42.
166. Schmalzried TP, Jasty M, and Harris WH. Periprosthetic bone loss in total hip arthroplasty. Polyethylene wear debris and the concept of the effective joint space. *J.Bone Joint Surg.Am.* 1992;74:849-63.
167. Schutzer SF, Grady-Benson J, Jasty M, O'Connor DO, Bragdon C, and Harris WH. Influence of intraoperative femoral fractures and cerclage wiring on bone ingrowth into canine porous-coated femoral components. *J.Arthroplasty* 1995;10:823-9.
168. Schwartz JTJ, Mayer JG, and Engh CA. Femoral fracture during non-cemented total hip arthroplasty. *J.Bone Joint Surg.Am.* 1989;71:1135-42.
169. Schwartz JT, Jr., Engh CA, Forte MR, Kukita Y, and Grandia SK. Evaluation of initial surface apposition in porous-coated acetabular components. *Clin.Orthop* 1993;174-87.

## References

---

170. Scott RD, Turner RH, Leitzes SM, and Aufranc OE. Femoral fractures in conjunction with total hip replacement. *J.Bone Joint Surg.Am.* 1975;57:494-501.
171. Shanbhag AS, Hasselman CT, and Rubash HE. The John Charnley Award. Inhibition of wear debris mediated osteolysis in a canine total hip arthroplasty model. *Clin.Orthop* 1997;33-43.
172. Sharkey PF, Hozack WJ, Booth RE, Jr., and Rothman RH. Intraoperative femoral fractures in cementless total hip arthroplasty. *Orthop.Rev.* 1992;21:337-42.
173. Smart RC, Barbagallo S, Slater GL et al. Measurement of periprosthetic bone density in hip arthroplasty using dual-energy x-ray absorptiometry. Reproducibility of measurements. *J Arthroplasty* 1996;11:445-52.
174. Soballe K, Brockstedt-Rasmussen H, Hansen ES, and Bunger C. Hydroxyapatite coating modifies implant membrane formation. Controlled micromotion studied in dogs. *Acta Orthop.Scand.* 1992;63:128-40.
175. Soballe K, Gotfredsen K, Brockstedt-Rasmussen H, Nielsen PT, and Rechnagel K. Histologic analysis of a retrieved hydroxyapatite-coated femoral prosthesis. *Clin.Orthop* 1991;255-8.
176. Soballe K, Hansen ES, Brockstedt-Rasmussen H, and Bunger C. Hydroxyapatite coating converts fibrous tissue to bone around loaded implants. *J.Bone Joint Surg.Br.* 1993;75:270-8.
177. Soballe K, Hansen ES, Brockstedt-Rasmussen H et al. Fixation of titanium and hydroxyapatite-coated implants in arthritic osteopenic bone. *J Arthroplasty* 1991;6:307-16.
178. Soballe K, Hansen ES, Brockstedt-Rasmussen H et al. Gap healing enhanced by hydroxyapatite coating in dogs. *Clin.Orthop* 1991;300-7.
179. Soballe K, Hansen ES, Brockstedt-Rasmussen H, Pedersen CM, and Bunger C. Hydroxyapatite coating enhances fixation of porous coated implants. A comparison in dogs between press fit and noninterference fit. *Acta Orthop.Scand.* 1990;61:299-306.
180. Soballe K, Hansen ES, Brockstedt-Rasmussen H, Pedersen CM, and Bunger C. Bone graft incorporation around titanium-alloy- and hydroxyapatite- coated implants in dogs. *Clin.Orthop.* 1992;282-93.
181. Soballe K, Hansen ES, Rasmussen H, Jorgensen PH, and Bunger C. Tissue ingrowth into titanium and hydroxyapatite-coated implants during stable and unstable mechanical conditions. *J.Orthop.Res.* 1992;10:285-99.
182. Soballe K, Toksvig-Larsen S, Gelineck J et al. Migration of hydroxyapatite coated femoral prostheses. A Roentgen Stereophotogrammetric study. *J.Bone Joint Surg.Br.* 1993;75:681-7.
183. Stuchin SA. Femoral shaft fracture in porous and press-fit total hip arthroplasty. *Orthop.Rev.* 1990;19:153-9.
184. Sugano N, Noble PC, Kamaric E, Salama JK, Ochi T, and Tullos HS. The morphology of the femur in developmental dysplasia of the hip. *J.Bone Joint Surg.Br.* 1998;80:711-9.
185. Sugiyama H, Whiteside LA, and Engh CA. Torsional fixation of the femoral component in total hip arthroplasty. The effect of surgical press-fit technique. *Clin.Orthop* 1992;187-93.
186. Sumner DR, Turner TM, Purchio AF, Gombotz WR, Urban RM, and Galante JO. Enhancement of bone ingrowth by transforming growth factor-beta. *J Bone Joint Surg.Am.* 1995;77:1135-47.
187. Sutter.B., Legrand O, Hardouin P, and Bascoulergue G. Bone remodeling around cementless hydroxyapatite coated total hip arthroplasty: A prospective 1year follow-up by dual-energy-x-ray absorptiometry in 30 subjects. *J Bone Miner Res* 1994;9 (suppl 1):275.
188. Taylor MM, Meyers MH, and Harvey JP, Jr. Intraoperative femur fractures during total hip replacement. *Clin.Orthop.* 1978;96-103.
189. Teti A, Tarquilio A, Grano M et al. Effects of calcium-phosphate-based materials on proliferation and alkaline phosphatase activity of newborn rat periosteal cells in vitro. *J Dent.Res* 1991;70:997-1001.
190. Therkelsen AJ. Vurdering af metodenøjagtighed på basis af en serie dobbeltbestemmelser. In: *Therkelsen AJ, ed. Medicinsk statistik.* Aarhus: FADL's Forlag, 1983:79-81.
191. Thomsen MN, Breusch SJ, Aldinger PJ et al. Robotically-milled bone cavities. A comparison with hand-broaching in different types of cementless hip stems. *Acta Orthop Scand.* 2002;73:379-85.
192. Toksvig-Larsen S, Jorn LP, Ryd L, and Lindstrand A. Hydroxyapatite-enhanced tibial prosthetic fixation. *Clin.Orthop* 2000;192-200.
193. Toni A, Ciaroni D, Sudanese A et al. Incidence of intraoperative femoral fracture. Straight-stemmed versus anatomic cementless total hip arthroplasty. *Acta Orthop.Belg.* 1994;60:43-54.
194. Tonino AJ, Therin M, and Doyle C. Hydroxyapatite-coated femoral stems. Histology and histomorphometry around five components retrieved at post mortem. *J Bone Joint Surg.Br.* 1999;81:148-54.

## References

---

195. Turner RH, Mattingly DA, and Scheller A. Femoral revision total hip arthroplasty using a long-stem femoral component. Clinical and radiographic analysis. *J Arthroplasty* 1987;2:247-58.
196. Turner TM, Urban RM, Sumner DR, and Galante JO. Revision, without cement, of aseptically loose, cemented total hip prostheses. Quantitative comparison of the effects of four types of medullary treatment on bone ingrowth in a canine model. *J Bone Joint Surg.Am.* 1993;75:845-62.
197. Vail, T., Channer, M., and Glisson, R. The effect of bone cavity preparation method on implant fixation. *Trans Orthop Res Soc*, 25, 2000.
198. Van Ham G, Denis K, Vander SJ et al. Machining and accuracy studies for a tibial knee implant using a force- controlled robot. *Comput.Aided Surg.* 1998;3:123-33.
199. van Rietbergen B, Huiskes R, Weinans H, Sumner DR, Turner TM, and Galante JO. ESB Research Award 1992. The mechanism of bone remodeling and resorption around press-fitted THA stems. *J Biomech.* 1993;26:369-82.
200. Wang JS, Tagil M, and Aspenberg P. Load-bearing increases new bone formation in impacted and morselized allografts. *Clin.Orthop* 2000;274-81.
201. Whitehouse WJ. The quantitative morphology of anisotropic trabecular bone. *J.Microsc.* 1974;101 Pt 2:153-68.
202. Whiteside LA and Easley JC. The effect of collar and distal stem fixation on micromotion of the femoral stem in uncemented total hip arthroplasty. *Clin.Orthop* 1989;145-53.
203. Wilkinson JM, Peel NF, Elson RA, Stockley I, and Eastell R. Measuring bone mineral density of the pelvis and proximal femur after total hip arthroplasty. *J Bone Joint Surg.Br.* 2001;83:283-8.
204. Wilkinson JM, Stockley I, Peel NF et al. Effect of pamidronate in preventing local bone loss after total hip arthroplasty: a randomized, double-blind, controlled trial. *J Bone Miner.Res* 2001;16:556-64.
205. Williams DF. *Definitions in biomaterials.* In: Williams DF, ed. Amsterdam: Elsevier, 1987:1-72.
206. Williams DF, Black J, Doherty PJ. *Second consensus on definitions in biomaterials.* In: Doherty PJ, ed. Biomaterial-tissue interfaces; Advances in biomaterials. London: Elsevier, 1992:525-33.
207. Williams JL and Lewis JL. Properties and an anisotropic model of cancellous bone from the proximal tibial epiphysis. *J Biomech.Eng* 1982;104:50-6.
208. Wolff J. *The Law of Bone Remodelling (Das Gesetz der Transformation der Knochen).* Translated by Maquet P and Furlong R, 1986. Berlin: Springer, 1892.
209. Wolff D, Goldberg VM, and Stevenson S. Histomorphometric analysis of the repair of a segmental diaphyseal defect with ceramic and titanium fibermetal implants: effects of bone marrow. *J Orthop Res* 1994;12:439-46.
210. Yoshinari M, Oda Y, Inoue T, Matsuzaka K, and Shimono M. Bone response to calcium phosphate-coated and bisphosphonate-immobilized titanium implants. *Biomaterials* 2002;23:2879-85.
211. Yu, L., Clark, J. G., Dai, Q. G., Schulz, E. E., and Johnson, L. L. Improving initial mechanical fixation of a porous coated femoral stem by a cancellous bone compaction method. *Trans Orthop Res Soc*, 24, 1999.